THE JOURNAL OF UROLOGY
Vol. 105, April
Copyright © 1971 by The Williams & Wilkins Co.
Printed in U.S.A.

CALCIFICATION OF THE SEMINAL VESICLES AND VAS DEFERENS IN A UREMIC PATIENT

SHERMAN J. SILBER AND FRANKLIN D. MCDONALD

From the Urology Section, Department of Surgery and the Renal Unit, Department of Internal Medicine, The University of Michigan, Ann Arbor, Michigan

Calcification of the vas deferens has been considered a pathognomonic sign of diabetes mellitus since the definitive study by Wilson and Marks in 1951.[1] They reported on 60 cases of calcification of the vas deferens, 56 of which were associated with long-term diabetes mellitus. The average age of the patients was 50 years; the youngest patient was 29. Arterial calcifications also were present in 53 cases. The average duration of diabetes before calcifications were seen was 18 years. Culver and Tannenhaus reported on 11 of 100 diabetic patients who had calcification of the vas deferens.[2] These investigators believe that vas deferens calcifications were more specific for diabetes mellitus than were vascular calcifications. Camiel reported on 4 additional cases.[3] No symptoms were associated with this condition and the calcifications were usually incidental findings on x-rays of male diabetics taken for other reasons.

Chronically uremic patients have parathyroid hyperfunction, usually a secondary phenomenon. Occasionally these glands become so enlarged and overactive that they behave autonomously and the serum calcium then rises persistently to normal or higher levels. There is a tendency for soft tissue calcification to occur in such patients. Our presentation is of a unique case of non-inflammatory calcification of the seminal vesicles and vas deferens in a young, non-diabetic, chronically uremic patient.

CASE REPORT

In January 1968 a 17-year-old white male youth was noted to have hypertension and progressive loss of renal function. In July renal biopsy confirmed the diagnosis of subacute glomerulonephritis. He had no history of tuberculosis, rheumatic fever or diabetes mellitus. He was allergic to penicillin. Both parents were in good health. The patient had had no sexual experience. He had no history of dysuria, urgency, frequency, chills or sweats.

He was admitted to the hospital on March 3, 1969. Blood pressure was 170/120. Pulse was 110 and regular. He appeared chronically ill and was continually scratching himself. The left border of the heart was enlarged to 2 cm. lateral to the left mid-clavicular line and a vigorous heave was noted. The liver was palpated 2 cm. below the costal margin at the right mid-clavicular line. Rectal examination revealed bilaterally hard, non-tender seminal vesicles.

Cystometric examination revealed a small capacity bladder and endoscopy showed a normal prostate and urethra. Chest film showed mild cardiomegaly but no pulmonary disease and no sign of old tuberculosis. Soft tissue calcifications in the hand suggested hyperparathyroidism. X-rays of the pelvis revealed linear areas of calcification in the vas deferens and seminal vesicles as well as generalized, diffuse bony demineralization (fig. 1). Old tuberculin skin test was negative. Serum creatinine was 13.0 mg. per cent, blood urea nitrogen 85 mg. per cent, serum calcium 7.3 mg. per cent and phosphorus 12.1 mg. per cent. Fasting blood sugar values were 107, 88, 90 and 102 mg. per cent on different days. Urinalysis showed 3 plus albumin, 5 to 10 red and 25 to 40 white blood cells per high power field and occasional oval fat bodies.

The patient had been on intermittent hemodialysis at another hospital but began on regular hemodialysis March 20, 1969, 3 times weekly for 6 hours each time with a twin-coil 145 Travenol RSP dialyzer. After a month his condition stabilized. On August 6 he received a renal allograft from his mother and underwent bilateral nephrectomy. Initially acute tubular necrosis developed but the patient recovered by Septem-

Accepted for publication May 13, 1970.

[1] Wilson, L. L. and Marks, J. H.: Calcification of vas deferens: its relation to diabetes mellitus and arteriosclerosis. New Engl. J. Med., **245:** 321, 1951.

[2] Culver, G. J. and Tannenhaus, J.: Calcification of vas deferens in diabetes. J.A.M.A., **173:** 648, 1960.

[3] Camiel, M. R.: Calcification of vas deferens associated with diabetes. J. Urol., **86:** 634, 1961.

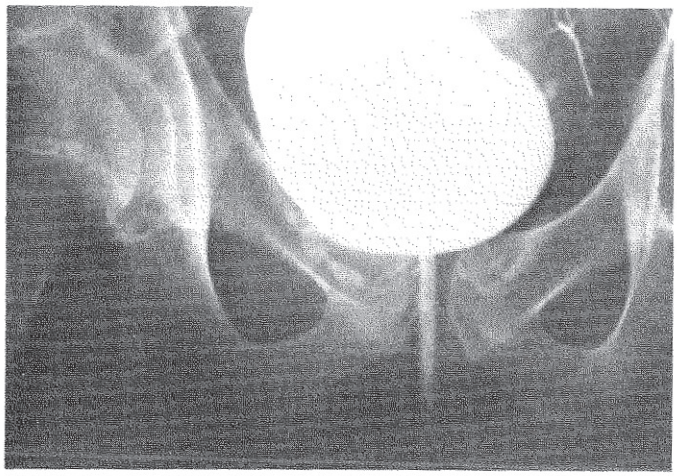

FIG. 1. X-ray shows calcified seminal vesicles and vas deferens. Contrast medium is in bladder

ber 2. An abscess was drained on August 17 which healed within a month and the patient was discharged from the hospital in mid September. X-rays showed no change in the calcification of the seminal vesicles or vas deferens.

Microscopic examination of the kidneys showed proliferative and sclerotic glomerulonephritis with capsular adhesions and no evidence of tuberculosis. Serum calcium and phosphorus values were recorded from July 1968 to September 1969 (see table).

	Calcium (mg.%)	Phosphorus (mg.%)
July	7.7	5.1
March	7.3	12.1
April	8.9	5.2
May	11.5	5.0
July	11.2 11.5	6.6 10.4
	11.4 11.2	9.5 8.4
August	10.3 9.6	2.2 5.8
	9.1	3.1
September	9.2	5.8

DISCUSSION

In the nineteenth century seminal vesicle calcification was thought to be caused entirely by chronic inflammation. However, at the turn of the century, George observed calcification of the seminal vesicles of elderly men at autopsy which was not associated with any inflammatory process.[4] He thought that calcification was due to a senile change in the muscularis rather than to gonorrhea or tuberculosis. The first case of seminal vesicle calcification shown by x-ray was initially misinterpreted as being a bladder stone by Kretschmer in 1922.[5] This case was secondary to tuberculosis. Marks and Ham reported on 7 cases of vas deferens calcification. Four cases were not associated with any inflammation but these patients were all diabetics. The other 3 patients did not have diabetes mellitus but did have a history of gonorrhea, prostatitis and urinary tract obstruction.[6] O'Conor and Crowley reported on a single case of bilateral vasa deferentia calcification in a 73-year-old man with chronic inflammation who was also a diabetic.[7] It appeared that seminal vesicle and vas deferens calcifications were either atrophic senile changes or the result of tuberculosis or other inflammatory conditions.

Anderson reported a case of calcified vasa deferentia and seminal vesicles, not associated with any chronic infection, in a person who had had diabetes mellitus for 13 years.[8] He maintained that calcification of the seminal vesicles was due to tuberculosis, gonorrhea or other inflammatory conditions, whereas calcification of the vas deferens was due to old age or diabetes. Since both seminal vesicles and vasa deferentia were calcified

[4] George, S.: Calcification of the vas deferens and the seminal vesicles. J.A.M.A., **47:** 103, 1906.

[5] Kretschmer, H. L.: Calcification of seminal vesicles. J. Urol., **7:** 67, 1922.

[6] Marks, J. H. and Ham, D. P.: Calcification of vas deferens. Amer. J. Roentgenol., **47:** 859, 1942.

[7] O'Conor, V. J. and Crowley, E.: Bilateral calcification of the vasa deferentia. Quart. Bull. Northwestern Univ. Med. School, **21:** 28, 1947.

[8] Anderson, P. E.: Calcification of the vasa deferentia. Acta Radiol., **34:** 89, 1950.

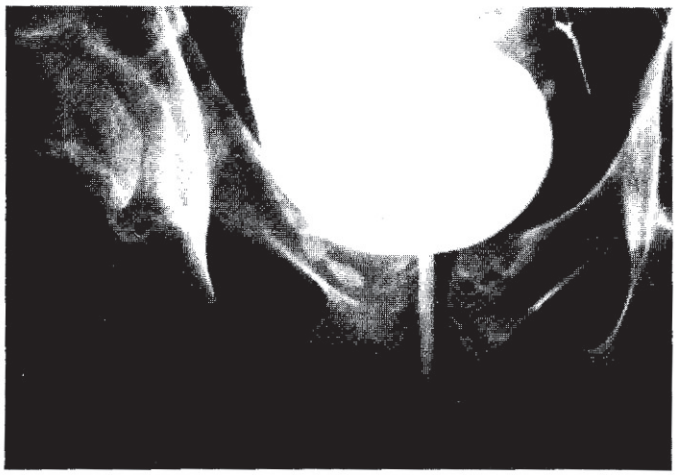

FIG. 1. X-ray shows calcified seminal vesicles and vas deferens. Contrast medium is in bladder

ber 2. An abscess was drained on August 17 which healed within a month and the patient was discharged from the hospital in mid September. X-rays showed no change in the calcification of the seminal vesicles or vas deferens.

Microscopic examination of the kidneys showed proliferative and sclerotic glomerulonephritis with capsular adhesions and no evidence of tuberculosis. Serum calcium and phosphorus values were recorded from July 1968 to September 1969 (see table).

	Calcium (mg.%)	Phosphorus (mg.%)
July	7.7	5.1
March	7.3	12.1
April	8.9	5.2
May	11.5	5.0
July	11.2 11.5	6.6 10.4
	11.4 11.2	9.5 8.4
August	10.3 9.6	2.2 5.8
	9.1	3.1
September	9.2	5.8

DISCUSSION

In the nineteenth century seminal vesicle calcification was thought to be caused entirely by chronic inflammation. However, at the turn of the century, George observed calcification of the seminal vesicles of elderly men at autopsy which was not associated with any inflammatory process.[4] He thought that calcification was due to a senile change in the muscularis rather than to gonorrhea or tuberculosis. The first case of seminal vesicle calcification shown by x-ray was initially misinterpreted as being a bladder stone by Kretschmer in 1922.[5] This case was secondary to tuberculosis. Marks and Ham reported on 7 cases of vas deferens calcification. Four cases were not associated with any inflammation but these patients were all diabetics. The other 3 patients did not have diabetes mellitus but did have a history of gonorrhea, prostatitis and urinary tract obstruction.[6] O'Conor and Crowley reported on a single case of bilateral vasa deferentia calcification in a 73-year-old man with chronic inflammation who was also a diabetic.[7] It appeared that seminal vesicle and vas deferens calcifications were either atrophic senile changes or the result of tuberculosis or other inflammatory conditions.

Anderson reported a case of calcified vasa deferentia and seminal vesicles, not associated with any chronic infection, in a person who had had diabetes mellitus for 13 years.[8] He maintained that calcification of the seminal vesicles was due to tuberculosis, gonorrhea or other inflammatory conditions, whereas calcification of the vas deferens was due to old age or diabetes. Since both seminal vesicles and vasa deferentia were calcified

[4] George, S.: Calcification of the vas deferens and the seminal vesicles. J.A.M.A., **47:** 103, 1906.

[5] Kretschmer, H. L.: Calcification of seminal vesicles. J. Urol., **7:** 67, 1922.

[6] Marks, J. H. and Ham, D. P.: Calcification of vas deferens. Amer. J. Roentgenol., **47:** 859, 1942.

[7] O'Conor, V. J. and Crowley, E.: Bilateral calcification of the vasa deferentia. Quart. Bull. Northwestern Univ. Med. School, **21:** 28, 1947.

[8] Anderson, P. E.: Calcification of the vasa deferentia. Acta Radiol., **34:** 89, 1950.

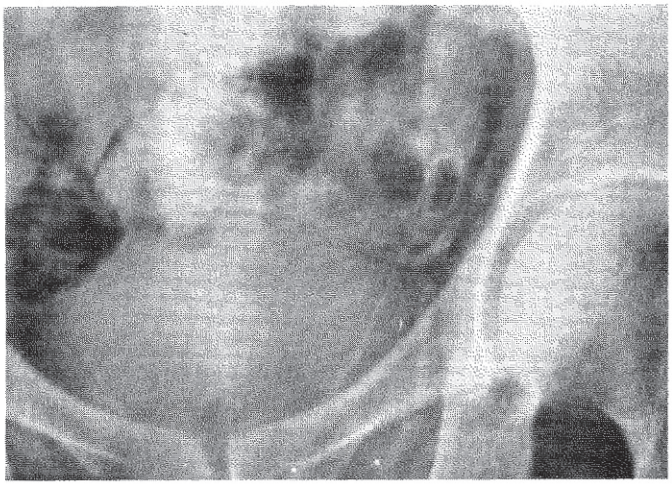

FIG. 2. X-ray of chronic uremic patient shows pelvic calcifications which could be in vas deferens but are probably vascular.

in his case he could not support this dichotomy. However, 1 year later Wilson and Marks reported on only the vas deferens calcification in diabetes mellitus and failed to consider the seminal vesicle. Gaca reported on a case of vas deferens calcification clearly caused by tuberculosis rather than diabetes or old age.[9]

Thus, it is fairly clear that arbitrary separation of the etiologies of seminal vesicle calcification and vas deferens calcification is without basis. Diabetes mellitus and senile atrophy are common causes of calcification of both structures (fig. 2). Tuberculosis and other forms of chronic inflammation are perhaps less common causes. This case presents another cause for this rare but useful radiologic sign. Chronic uremia, with its unavoidable secondary hyperparathyroidism, may now also be incriminated in calcification of the vas deferens or seminal vesicle. Our patient did not have any history or evidence of tuberculosis or other chronic urogenital infections. He had no diabetes mellitus. He did have persistently elevated serum calcium levels, indicating that the parathyroid glands were behaving autonomously.

[9] Gaca, A.: Verkalkungen der Samenwege. Z. Urol., **55:** 406, 1962.

SUMMARY

Diabetes mellitus, tuberculosis and chronic urogenital infections are recognized causes of seminal vesicle and vas deferens calcification.

A case is presented in which calcification of the seminal vesicles and vas deferens occurred in a uremic patient with secondary hyperparathyroidism. This must now be considered an additional cause for calcification of these structures.

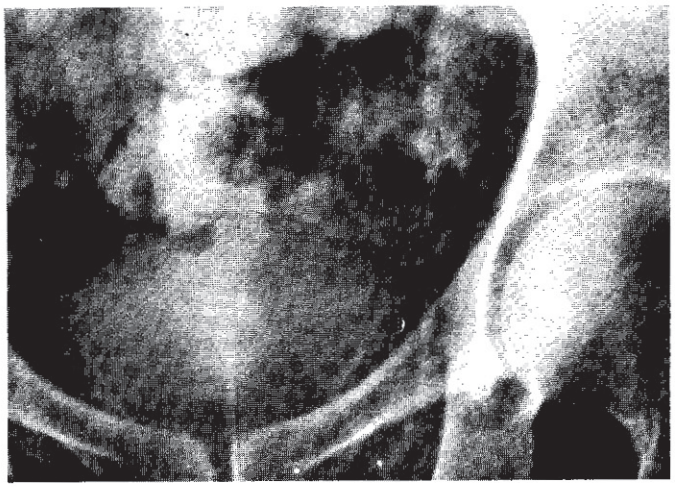

FIG. 2. X-ray of chronic uremic patient shows pelvic calcifications which could be in vas deferens but are probably vascular.

in his case he could not support this dichotomy. However, 1 year later Wilson and Marks reported on only the vas deferens calcification in diabetes mellitus and failed to consider the seminal vesicle. Gaca reported on a case of vas deferens calcification clearly caused by tuberculosis rather than diabetes or old age.[9]

Thus, it is fairly clear that arbitrary separation of the etiologies of seminal vesicle calcification and vas deferens calcification is without basis. Diabetes mellitus and senile atrophy are common causes of calcification of both structures (fig. 2). Tuberculosis and other forms of chronic inflammation are perhaps less common causes. This case presents another cause for this rare but useful radiologic sign. Chronic uremia, with its unavoidable secondary hyperparathyroidism, may now also be incriminated in calcification of the vas deferens or seminal vesicle. Our patient did not have any history or evidence of tuberculosis or other chronic urogenital infections. He had no diabetes mellitus. He did have persistently elevated serum calcium levels, indicating that the parathyroid glands were behaving autonomously.

[9] Gaca, A.: Verkalkungen der Samenwege. Z. Urol., **55:** 406, 1962.

SUMMARY

Diabetes mellitus, tuberculosis and chronic urogenital infections are recognized causes of seminal vesicle and vas deferens calcification.

A case is presented in which calcification of the seminal vesicles and vas deferens occurred in a uremic patient with secondary hyperparathyroidism. This must now be considered an additional cause for calcification of these structures.