

## TRANSPLANTATION OF A HUMAN TESTIS FOR ANORCHIA\*

SHERMAN J. SILBER, M.D.†

*St. Luke's Hospital-West, St. Louis, Missouri 63017*

*One of two genetically identical twins (30 years old) had been born with two normal testes and the other with none. In the anorchic twin, preoperative serum follicle-stimulating hormone (FSH) and luteinizing hormone (LH) levels were extremely high, and the serum testosterone level was extremely low. In the twin with two testes, preoperative serum FSH, LH, and testosterone levels were normal. After successful transplantation of a testis from the twin with two testes to the twin with no testes, using the microvascular technique, the recipient twin developed a normal serum testosterone level within 2 hours of surgery; his FSH and LH levels came down toward a normal range more slowly over the ensuing 4 weeks. The donor's FSH level became mildly elevated 2 days postoperatively but returned to normal by 3 months. Thereafter, serum FSH, LH, and testosterone levels remained persistently normal in both twins. In the donor, pre- and postoperative sperm counts were normal. Preoperatively the recipient's semen had no sperm, but postoperatively the sperm content has slowly increased to normal levels. Fertil Steril 30:181, 1978*

A 30-year-old male had been born with no testes and his identical twin brother was born with two normal testes in the scrotum. They requested a testicular transplant so that the anorchic twin would no longer have to take testosterone injections and also so that he might possibly be able to father children. The twin with testes went through normal puberty at 13 years of age and by age 30 had fathered three healthy children. The twin with no testes had not gone through puberty, and at age 14 underwent a lengthy course of chorionic gonadotropin injections. When no response to chorionic gonadotropin was noted, he underwent an extensive surgical exploration and no testes were discovered. On the right side, he was noted to have a vas deferens in the scrotum which ended in what was assumed to be an atrophic testicular remnant.

He continued to retain a eunuchoid appearance with no pubertal changes until age 18,

when varying doses of depo-testosterone were begun. This regimen induced normal puberty, and secondary sex characteristics developed. He underwent a rapid growth spurt at this time, so that by age 20, he was 5 feet 11 inches tall, whereas his brother with testes had stopped growing much earlier, at 5 feet 7 inches.

The anorchic brother was then able to have an active sex life, but noted lability in his mood and drive when relying on monthly testosterone injections. On weekly injections he had a more stable mood pattern. Shortly before the transplantation, he relied on weekly intramuscular injections of depo-testosterone, 200 mg. For the past 5 years he had been actively searching for medical authorities who would consider a testicular transplant.

### PREOPERATIVE STUDIES

*Donor.* The donor was 5 feet 7 inches tall, weighed 147 pounds, and his physical examination was normal in all respects. His serum follicle-stimulating hormone (FSH) level was 11 mIU/ml (normal male range, 3 to 20 mIU/ml) and his luteinizing hormone (LH) level was 14 mIU/ml (normal male range, 6 to 30 mIU/ml). His

Received February 20, 1978; accepted March 23, 1978.

\*Presented in part at the American College of Surgeons, October 18, 1977, Dallas, Tex.

†Reprint requests: Sherman J. Silber, M.D., 456 North New Ballas Road, St. Louis, Mo. 63141. 63141.



serum testosterone level was 626 ng/100 ml (normal male range, 300 to 1200 ng/100 ml). His sperm count (performed twice) was 44 million sperm/ml, with 85% motility and 90% normal forms, a volume of 3.5 ml, and pH 8.0; on another occasion, 76 million sperm/ml with 85% motility and almost all normal forms, a volume of 3 ml, and pH 8.0. Chest x-ray, complete blood count, and SMA-12 chemical profile were normal. An intravenous pyelogram was normal, and a scrotal scan showed normal activity bilaterally in each scrotum.

*Recipient.* The patient was 5 feet 11½ inches tall and weighed 150 pounds. Physical examination was normal except for a well-healed lower abdominal surgical scar, complete absence of testes in the scrotum, and a palpable vas deferens on the right. He had normal secondary sex characteristics.

The patient had been taken off his weekly testosterone injections for 1 month prior to the scheduled surgery. At that time his serum FSH was 96 mIU/ml and his serum LH was 110 mIU/ml. His serum testosterone was 76 ng/100 ml (lower limit of normal in the male is 300 ng/100

ml). A semen analysis revealed no spermatozoa, a volume of 3.0 ml, pH 8.0, and a positive fructose test. Chest x-ray, complete blood count, and SMA-12 chemical profile were normal. An intravenous pyelogram was normal bilaterally, and a scrotal scan revealed no radioactivity in either scrotum.

#### OPERATIVE TECHNIQUE

The microvascular technique for testicular homotransplantation is very similar to that for autotransplantation.<sup>1,2</sup> The donor testis was removed through a right inguinal incision at the level of the internal inguinal ring, where there were one testicular artery (0.5 mm in diameter) and two testicular veins (1.5 mm in diameter) (Fig. 1). The vas deferens (inner diameter 0.3 mm, outer diameter 2.0 mm) was also divided at this level. A similar right inguinal incision was made in the recipient, and the testicular artery of the donor was anastomosed to the deep inferior epigastric artery (1.5 mm in diameter) of the recipient after spatulating the donor testicular artery. The two spermatic veins of the donor were

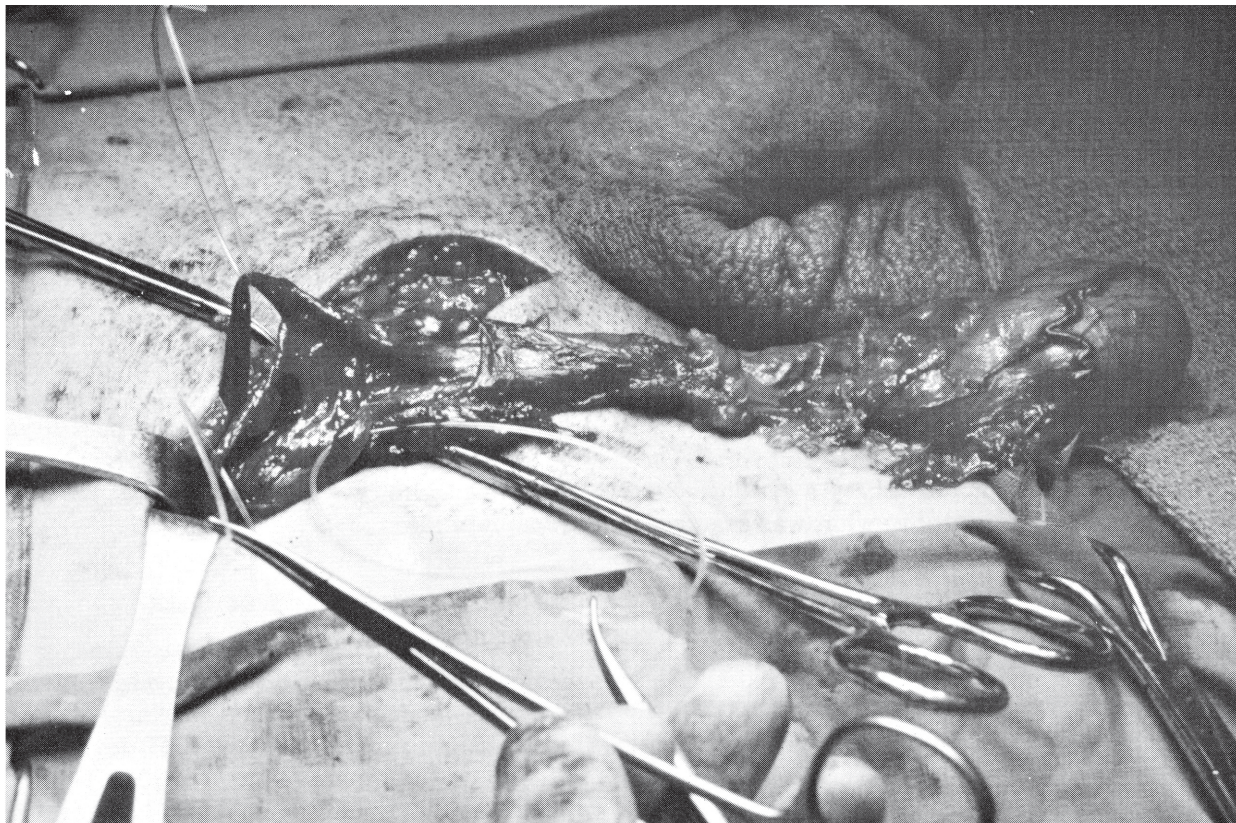


FIG. 1. Donor testis is prepared for transplant. Two spermatic veins, the internal spermatic artery, and vas deferens have been at the internal inguinal ring.



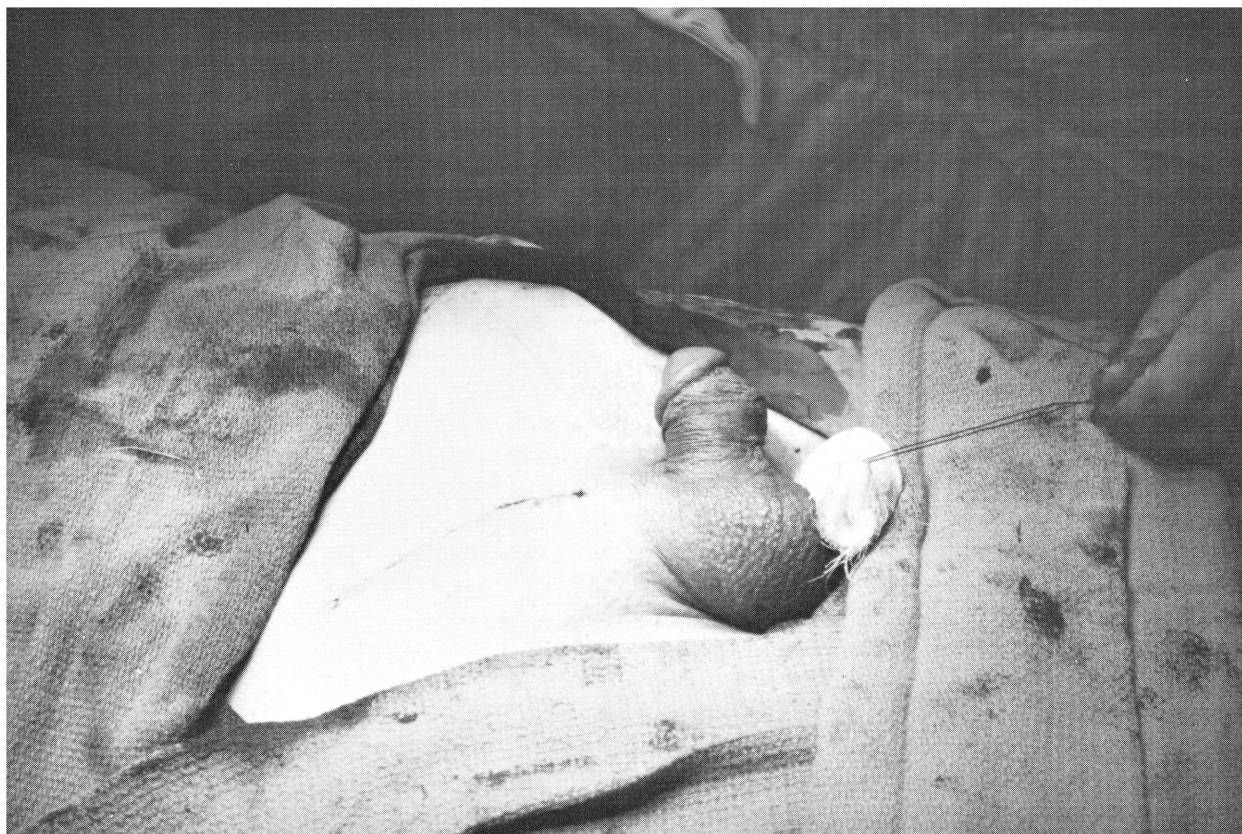

FIG. 2. Testis now in recipient.

then anastomosed to the superficial and deep inferior epigastric veins of the recipient. Interrupted sutures of 9-0 nylon were used for all anastomoses, and the cold ischemia time was 1.5 hours. Finally, the vas deferens of the donor was anastomosed to that of the recipient, using a technique that has also been described in great detail.<sup>3-5</sup> All anastomoses were performed under  $\times 16$  to  $\times 25$  magnification under a Zeiss operating microscope, and excellent flow was observed through the vessels. Bleeding was then noted along the

cut edge of the donor vas deferens. When the anastomoses were completed, the testis was placed in the scrotum in its proper anatomical position, and the incision was closed (Fig. 2). Doppler readings were taken in the cord area just above the testis at regular intervals, and demonstrated good flow.

#### POSTOPERATIVE STUDIES

*Donor.* The donor's postoperative sperm count and hormone values are summarized in Table 1.

TABLE 1. *Testis Donor*

Determination <sup>a</sup>	Days postoperative											
	-1	0 (2 hr)	1	2	3	4	5	6	7	90	240	
Serum testosterone (ng/100 ml)	943											
	626	385	392	353	414					550	450	
Serum LH (mIU/ml)	27											
	14	17	16	18	21					19	11	
Serum FSH (mIU/ml)	12											
	11	11	11	19	23					17.9	15	
Sperm count												
Density (million/ml)	44					47				53		
Motility (%)	85%					85%				50%		
Density (million/ml)	76											
Motility (%)	85%											

<sup>a</sup>Laboratory normal range: testosterone, 300 to 1200 ng/100 ml; LH, 6 to 30 mIU/ml; FSH, 3 to 20 mIU/ml.



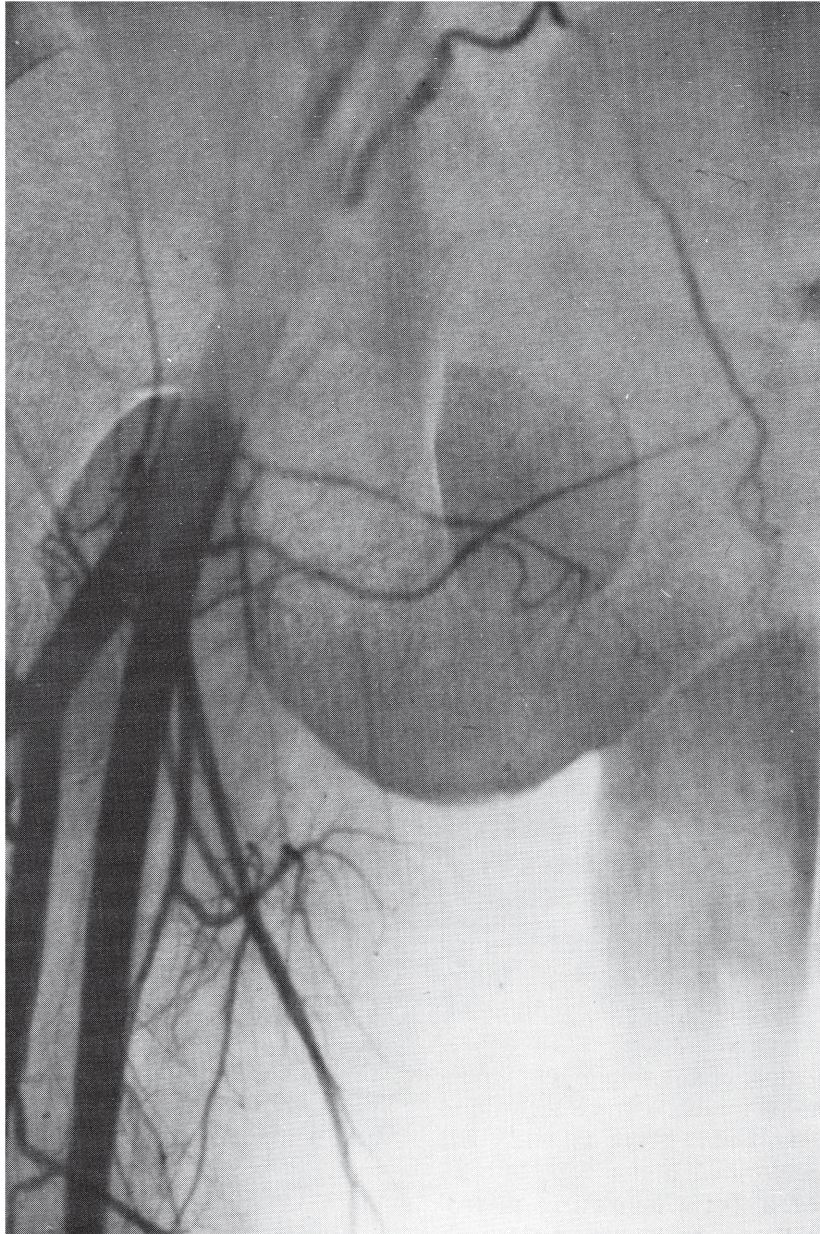


FIG. 3. Arteriogram showing anastomosis of recipient inferior epigastric artery (1.5 mm) to donor internal spermatic artery (0.5 mm).

Testosterone remained in the normal range. There was a subtle elevation in FSH during the first 3 days postoperatively, which came down to preoperative levels by 90 days. These changes were minimal, however, and the donor suffered no abnormality from unilateral orchiectomy.

*Recipient.* The excised end of the vas deferens was histologically unremarkable. A right testicular arteriogram performed via the right iliac artery 7 days postoperatively revealed a normal, patent anastomosis between the deep inferior epigastric artery of the recipient and the internal

spermatic artery of the donor testis (Figs. 3 and 4).

The recipient's postoperative sperm count and hormone values are summarized in Table 2. The sperm count taken at 7 days postoperatively was 3.5 million sperm/ml with 35% motility, a volume of 3.0 ml, and pH 8.0. The sperm count on the following day was 2.5 million sperm/ml with 25% motility. The sperm count obtained 1 month postoperatively showed only a very rare, nonmotile sperm. In subsequent months it then began to rise slowly again to its present normal range



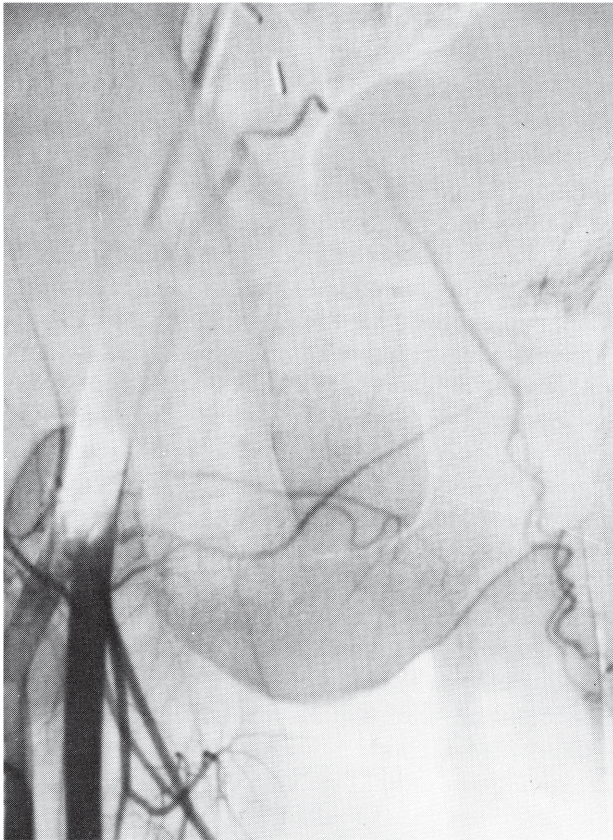


FIG. 4. Later phase of arteriogram showing good blood supply to transplanted testis.

of 15 million sperm/ml with over 50% motility and 90% normal morphology.

Blood samples for hormone determinations were obtained at 2 hours after the microvascular clamps were removed and perfusion to the transplanted testis was re-established. The serum testosterone level jumped almost instantly to the normal range and then continued to increase slowly to higher levels over the next 40 days. Serum FSH and LH levels came down more slowly, and did not really reach the normal range until 30 to 60 days postoperatively. However, the decline of FSH and LH from castrate levels to normal had begun by the 2nd postoperative day. The recipient continues to have normal hormone levels and normal sexual drive and activity, despite being on no medication since 1 month prior to surgery. His incision is well healed and his new testis looks just as though it were his.

DISCUSSION

Attaran et al.<sup>6</sup> described testicular transplants in dogs utilizing a nonmicroscopic technique which required excising a cuff of the anterior

TABLE 2. Testis Recipient

Determination <sup>a</sup>	Days postoperative														
	-1	0 (2 hr)	1	2	3	4	5	6	9	30	60	90	150	230	240
Serum testosterone (ng/100 ml)	81	348	311	378	551		569	630	528	740		470	830		
Serum LH (mIU/ml)	76														
Serum FSH (mIU/ml)	110	145	76	70	81		105	67	39	39	20		15		
Sperm count	94														
Density (million/ml)	96	115	115	82	66		52	50	35	17.4			14.8		
Motility (%)	0	0	0						3.4	Rare	0.83	1.0	9.5	18.0	8.0
Density (million/ml)	0	0							35%	0%	1%	20%	10%	50%	50%
Motility (%)									2.4					12.6	35%

<sup>a</sup>Laboratory normal range: testosterone, 300 to 1200 ng/100 ml; LH, 6 to 30 mIU/ml; FSH, 3 to 20 mIU/ml.



aortic wall along with the spermatic artery in order to have a segment large enough for anastomosis to a recipient vessel. The auto-transplants appeared to survive, but the homo-transplants were rejected. Their technique would not be applicable to human cases since it would involve extensive intra-abdominal exposure and vascular risk which neither the donor nor the recipient would be likely to agree to.

Lee et al.,<sup>7</sup> Altwein et al.,<sup>8</sup> and Gittes et al.<sup>9</sup> studied testicular transplantation in syngeneic rats and compared the results of simple testicular implantation with those obtained after a vascularized transplant. It was very clear from their studies that simple implantations of testicular tissue did not result in an endocrinologically viable testis. Syngeneic rats that had undergone bilateral orchiectomy with vascular transplantation of a new testis maintained normal FSH and LH levels. However, rats given simple testicular implants after bilateral orchiectomy developed extremely high FSH and LH levels.

Human testicular transplantation was made possible by sophisticated microsurgical techniques which allowed both donor and recipient to be operated upon through a simple inguinal incision without intraperitoneal exploration. One-half millimeter vessels could be anastomosed with very good assurance of continued patency. The transplanted testis is obviously functioning as a normal endocrine gland as evidenced by the return of FSH, LH, and testosterone levels to normal values. It is interesting that the testosterone level became normal so rapidly despite a much slower decline in gonadotropin levels.

Sperm seen in the recipient's ejaculate 7 and 8 days postoperatively clearly were produced while the testis was in the donor. The decline in sperm count thereafter would imply a temporary interruption of spermatogenesis related to the ischemia time. However, the possibility of a defect in conduction of peristalsis along the denervated vas deferens cannot be ruled out. Subsequent improvement of sperm count could be due to recovery from the transient episode of ischemia or to reinnervation of the vas.

Animal studies by Smith<sup>10</sup> and Steinberger and Tjioe<sup>11</sup> indicate that the testis may tolerate as much as 2 to 4 hours of ischemia without severe damage. Beyond that interval it is clear that testicular recovery is poor. We feel now that with some technical innovations, the ischemia time for future such operations can be reduced

to 20 minutes. If so, it might help answer the question posed in this case by the temporary decrease in sperm count.

An interesting sidelight to this case would be the apparent implication that anorchia is an acquired in utero disease. These patients were genetically identical, but one had testes and the other did not. Anorchic patients generally do not have Müllerian structures, and this patient did not. Therefore, one could presume that a normal Müllerian inhibiting factor is present at the right time. Most patients with anorchia do have identifiable vasa deferentia.<sup>12</sup> It may be that functioning testes were present at the early stage of embryonic sex differentiation and degenerated later. Since Müllerian development is suppressed at about the same time that Wolffian development is stimulated, one would expect anorchic patients to have a vas deferens.

Since there are a fair number of individuals with anorchia who are dependent upon testosterone injections, the question of transplantation in nonidentical individuals naturally comes up. Patients on immunosuppressive therapy for renal transplants (prednisone, 5 mg to 30 mg/day, and Imuran, 1 mg to 2 mg/kg/day) are known to have fathered children and have normal sperm counts.<sup>13</sup> However, the application of this surgical procedure to nonidentical individuals awaits the development of safer methods of specific immunosuppression.

*Acknowledgments.* The author wishes to thank David Kracjovic, M.D., Michael Ribando, M.D., and the nursing staff for their assistance during this operation.

#### REFERENCES

1. Silber SJ: Microsurgery in clinical urology. *Urology* 6:150, 1975
2. Silber SJ, Kelly J: Successful autotransplantation of an intra-abdominal testis to the scrotum by microvascular technique. *J Urol* 115:452, 1976
3. Silber SJ: Microscopic technique for reversal of vasectomy. *Surg Gynecol Obstet* 143:630, 1976
4. Silber SJ: Perfect anatomical reconstruction of vas deferens with a new microscopic surgical technique. *Fertil Steril* 28:72, 1977
5. Silber SJ: Vasectomy and vasectomy reversal. *Fertil Steril* 29:125, 1978
6. Attaran SE, Hodges DV, Crary LS Jr, Van Galder GC, Lawson RK, Ellis LR: Homotransplants of the testis. *J Urol* 95:387, 1966
7. Lee S, Tung KSK, Orloff MJ: Testicular transplantation in the rat. *Transplant Proc* 3:586, 1971



8. Altwein JE, Lee S, Gittes RF: Testicular transplantation versus implantation: differentiation by gonadotrophin radioimmunoassay. *Invest Urol* 10:91, 1972
9. Gittes RF, Altwein JE, Yen SSC, Lee S: Testicular transplantation in the rat: long-term gonadotrophin and testosterone radioimmunoassay. *Surgery* 72:187, 1972
10. Smith GI: Cellular changes from graded testicular ischemia. *J Urol* 73:355, 1955
11. Steinberger E, Tjioe DY: Spermatogenesis in rat testes after experimental ischemia. *Fertil Steril* 20:639, 1969
12. Bergada C, Cleveland WW, Jones HW Jr, Wilkins L: Variants of embryonic testicular dysgenesis: bilateral anorchia and the syndrome of rudimentary testes. *Acta Endocrinol (Kbh)* 40:521, 1962
13. Baumgarten SR, Lindsay GK, Wise GJ: Fertility problems in the renal transplant patient. *J Urol* 118:991, 1977