

## Vasectomy and Its Microsurgical Reversal

*Sherman J. Silber, M.D.\**

Vasectomy is one of the most popular operations performed in the United States. Yet there has been a great deal of controversy about its effects and its reversibility. There are two major aspects of this problem. The first concerns techniques for obtaining a reliable reanastomosis. With modern microsurgery, accurate reanastomosis of the vas deferens should be achievable in almost every case. Although stricture formation will occur, this can usually be overcome with a reoperation. We will describe the surgical techniques in detail, so that the anatomical barrier to reversibility can be bridged.

The second aspect of the problem relates to the effects of vasectomy itself on the male reproductive system, which may prevent recovery of fertility despite an accurate microscopic anastomosis. It is very clear that despite the most elegant microsurgical technique for reanastomosis, some patients still do not recover fertility. We have to assume, therefore, that some sort of permanent damage occurred as a result of the vasectomy. If the factors that induce this damage in some patients can be identified, we might develop an approach towards vasectomy that would make it potentially more reversible. During the last two years of clinical investigation, we have come somewhat closer to understanding these factors.

### GENERAL CONSIDERATIONS

Conventional techniques for vasal reanastomosis have involved placing a splint of nylon or polyethylene into the two cut ends of the vas deferens and stitching the muscularis with three to eight 4-0 or 6-0 sutures. This sort of approach results in inaccurate mucosal alignment, leakage of sperm, granuloma, and a badly strictured reconnection of the inner lumen of the vas.<sup>1, 3, 4, 7, 8, 23</sup> Indeed, histologic sections of such anastomoses frequently demonstrate only fistulous interanastomosing channels or no discernible channel at all. Conventional va-

\*St. Lukes West Hospital, St. Louis, Missouri.

sovasostomy has generally yielded a 30 to 85 per cent incidence of sperm in the ejaculate, with a 5 to 25 per cent incidence of pregnancy.<sup>2</sup> In most of the reported clinical series there is no solid information regarding the type of original vasectomy performed; the actual sperm counts at various intervals postvasovasostomy; the type of sperm, if any, in the vas fluid at the time of vasovasostomy; or any characteristics of the patient that might have been correlated later with good or bad results. Thus, it has been impossible to differentiate the relative importance of surgical technique from other factors that might influence reversibility.

In this section the details of a microscopic technique used in a series of 450 patients will be discussed. This method appears to provide as satisfactory an anastomosis as is presently possible. In addition, the results of this series will be reviewed and those factors, other than a technically accurate reanastomosis, that may influence the recovery of fertility will be examined

### MICROSCOPIC TECHNIQUES

The anastomosis is performed under 16 to 25  $\times$  magnification (Figs. 1 and 2). The assistant grasps the anterior wall of the abdominal end of the vas deferens; the operator inserts his closed jeweler's forceps into the tiny lumen and by opening the forceps allows it to be more easily visualized. This lumen is about 0.33 mm in diameter, and visualizing it under the microscope makes one aware of how poorly one

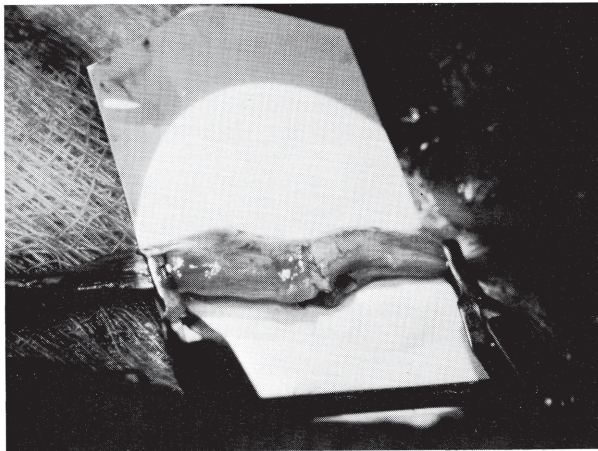


Figure 1. Completed anastomosis (macro view) showing vasovasostomy clamp. (From Silber, S. J.: *Microsurgery*. Baltimore, Williams & Wilkins, in press, with permission.)

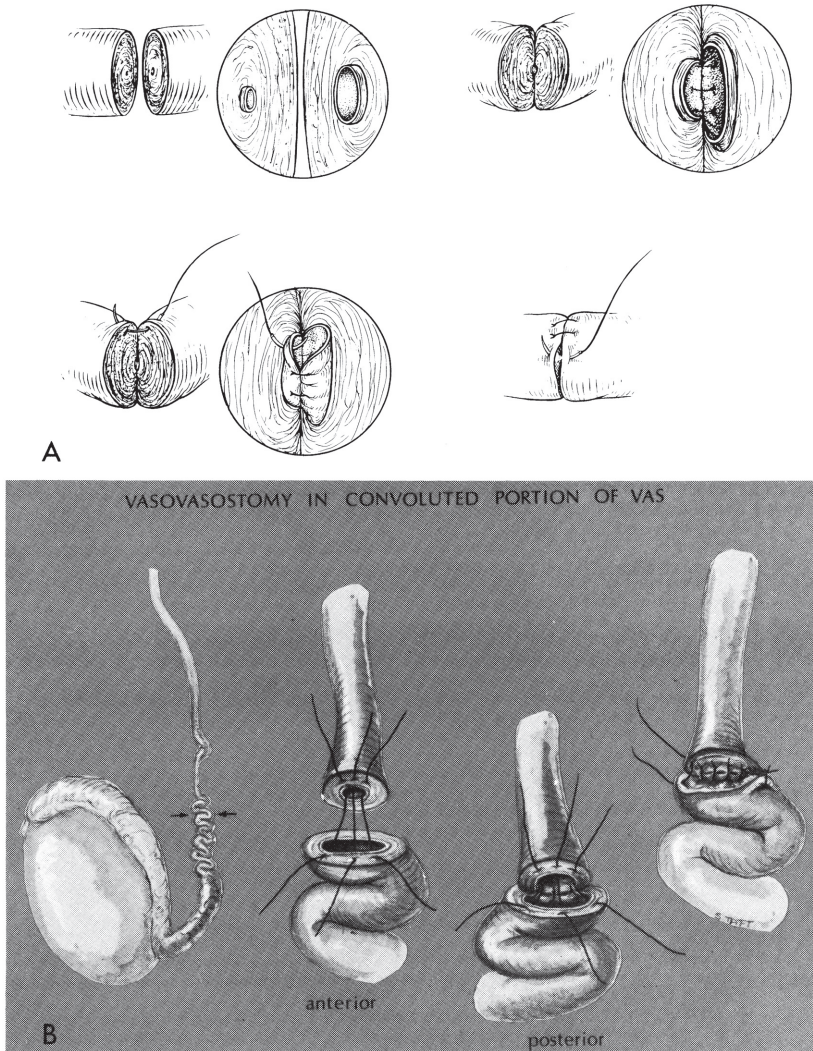


Figure 2. A, The two-layer anastomosis of the vas deferens. Note the importance of matching up the diameters of the lumens with interrupted 9-0 nylon sutures. This would be very difficult to perform accurately with continuous suturing. (From Silber, S. J.: Microscopic technique for reversal of vasectomy. *Surg. Gynecol. Obstet.*, 143:630, 1976.) B, The convoluted vas is just as easy to deal with using this technique. (From Silber, S. J.: Perfect anatomical reconstruction of vas deferens with a new microscopic surgical technique. *Fertil. Steril.*, 28:72, 1977, with permission.)

sees it with the naked eye. The operator then places the first mucosal suture anteriorly, making sure that the suture includes the elastic layer directly next to the mucosa. The suture is pulled through separately and then placed into the mucosa of the lumen on the testicular side of the vas. An instrument tie is performed and the suture is cut. A 9-0 nylon suture is used for the entire anastomosis. Anything larger will result in tissue reaction and may compromise the tiny lumen.

After this first suture is tied, visualization of the lumen may be increasingly difficult. The assistant, therefore, grasps the wall of the vas deferens again and rotates it towards him. This again allows visualization of the inner mucosal lining, and the surgeon places his jeweler's forceps into the lumen, placing the next anterior suture adjoining the first one. After the first three mucosal sutures are placed anteriorly in such a fashion, the entire vasovasostomy clamp is flipped around 180°, and what was the posterior wall of the vas deferens is now visualized in the anterior position.

At this point one can easily view the anterior row of sutures from the inside and inspect to see whether accurate mucosal alignment has been achieved. If an accurate mucosa-to-mucosa approximation has not been achieved, it is wise to replace the stitches. The lumens of unequal size need to be matched up. If the sutures are properly spaced, it is possible to match the shrunken mucosal lumen of the distal side with the dilated opening of the testicular side. The small lumen readily dilates up to the diameter of the larger lumen, and the sixth or seventh mucosal suture usually closes a tiny gap. There should be no inaccuracy in the lineup of these mucosal margins. When this is completed a water-tight and leakproof connection of the inner canal of the vas deferens should have been achieved; and the outer muscularis is sutured separately.

Some surgeons have advocated simply doing a one-layer anastomosis. The only reason that a two-layer anastomosis is suggested is that a better mucosal approximation can be achieved with this approach, and it really turns out to be easier. If, instead of doing a separate mucosal layer, one uses full-thickness stitches that traverse the muscularis and mucosa in one large bite, so much muscle is pulled into the anastomosis that the next stitch is very difficult to place accurately, because visualization of the mucosal edge of the lumen is obscured. In addition, with a through and through stitch there is almost always a muscle bridge between the two mucosal edges, and this allows leakage of sperm and formation of granuloma. Finally, it is very difficult to match up the shrunken lumen to the dilated lumen with full-thickness stitches. A separate mucosal layer allows a very precise, more leakproof connection.

Accurate suturing of the muscularis ensures adequate strength and support to the anastomosis and allows normal conduction of peristalsis essential for the propulsion of sperm from the epididymis into the ejaculate. The muscularis closure should not be relied upon for making the anastomosis leakproof. This goal must be accomplished by the mucosal layer. If the muscularis is relied upon for this purpose and

if the mucosal anastomosis is inadequate, then sperm will leak easily into this muscularis and create a granulomatous response with subsequent stricture formation. It is ironic that the mechanism that allows even the crudest efforts at vasovasostomy to permit some sperm to flow into the ejaculate (a sperm granuloma) is also the culprit responsible for a good deal of failures to get an adequate anastomosis.

In over 450 cases, we have not yet seen any in which an accurate anastomosis could not be achieved with this technique, no matter how large a segment of vas had been missing, and no matter how low in the convoluted portion the vasectomy had been performed. One to 2 per cent scar down later, but at least the type of vasectomy was not a factor in obtaining a good anastomosis. In fact, the majority of patients in our group had had their vasectomy in the convoluted portion.

Further details of these microsurgical techniques for the interested reader have been published elsewhere.<sup>2, 10-14, 16, 18-22</sup>

#### RESULTS WITH TWO-LAYER MICROSCOPIC TECHNIQUE

Approximately 450 patients have now been subjected to this technique and have been carefully studied both pre- and postoperatively in an effort to determine the factors that affect recovery of fertility.<sup>15, 17</sup> The overall pregnancy rate after one and a half years of followup on the first 42 unselected patients was 71 per cent. Very few patients have gotten pregnant before six months have passed and most of the pregnancies begin to show up between eight months and a year and a half. It is possible that the ultimate pregnancy rate will continue to increase in this initial group. An accurate assessment of pregnancy rate is not possible before a series has been followed for at least one and a half years. Although some patients achieve normal sperm counts within the first month and impregnate their wives immediately, this is certainly the exception. It is remarkable how long a full recovery of normal sperm count may require. The sperm count and motility tend to improve continually over the first two years of followup. Even patients who had impregnated their wives by three months continue to show gradual increases in sperm quantity and motility with long-term followup.

Despite this high rate of success and our enthusiasm for the two-layer microscopic technique, the failure of some patients to achieve fertility despite an accurate reanastomosis has made us very concerned about what sort of permanent testicular or epididymal damage created by the vasectomy might be averted in future vasectomies. Most of the large number of patients in this series have not been followed long enough to consider the results of pregnancy seriously, but since pregnancy (71 per cent) in the early series correlated very well with the quality of the sperm count, we can at least derive some preliminary information from evaluating the recovery of normal sperm counts, motility, and morphology in the larger number of patients who

have been operated upon more recently and who have had more carefully controlled observations made both pre- and postoperatively.

### Reoperation After Failure of Conventional Techniques

Fifty-three patients had previously been operated on unsuccessfully by excellent urologists, as evidenced by oligospermia or azoospermia and failure to impregnate their spouse. Of these patients, 23 had originally been considered successes surgically because of the presence of sperm in the ejaculate. Their failure to impregnate their wives was attributed to a variety of causes, most frequently sperm antibodies. Of those 23 patients, 13 had oligospermia with poor motility at the time that I reoperated upon them (Table 1) and 10 had changed from having sperm in the ejaculate postoperatively to being completely azoospermic (Table 2). In all these cases severe obstruction was noted at the site of the former anastomosis. All 13 of the patients with oligospermia and poor motility recovered normal sperm counts with normal motility and morphology after microscopic reoperation using this technique. Of the 10 patients who were azoospermic in this group, eight developed normal sperm counts after reoperation and two have not been given followup.

Considering all the 51 patients in this group that have been given followup, 41 recovered normal sperm counts after the reanastomosis. Surgically these were interesting cases because all involved the convoluted portion of the vas deferens and several involved the tail of the epididymis. Ten of the 51 patients failed to develop normal sperm counts after reoperation, but nine of these 10 patients had no sperm in their vas fluid on the testicular side of the obstruction at the time of the operation. Dividing the 51 patients into those whose vasectomy

**Table 1.** *Patients with Oligospermia and Infertility After Previous Attempts at Vasovasostomy*

| PA-<br>TIENT<br>No. | TIME<br>SINCE<br>VASEC-<br>TOMY<br>(YR.) | TIME<br>SINCE<br>UNSU-<br>CESSFUL<br>RE-<br>VERSAL | SPERM PRIOR TO<br>REOPERATION |          | TIME<br>SINCE<br>REOPERA-<br>TION | NEW SPERM  |          |
|---------------------|------------------------------------------|----------------------------------------------------|-------------------------------|----------|-----------------------------------|------------|----------|
|                     |                                          |                                                    | COUNT                         | MOTILITY |                                   | COUNT/CC   | MOTILITY |
| 1                   | 17                                       | 4 yr.                                              | 4,000,000/cc                  | 5%       | 1 yr.                             | 53,000,000 | 50%      |
| 3                   | 6                                        | 7 mo.                                              | Occas. Sperm                  | 0%       | 1 yr.                             | 86,000,000 | 60%      |
| 8                   | 6                                        | 8 mo.                                              | 7,000,000/cc                  | 5%       | 2 mo.                             | 42,000,000 | 50%      |
| 12                  | 4                                        | 3 yr.                                              | 5,000,000/cc                  | 1%       | 5 mo.                             | 55,000,000 | 40%      |
| 16                  | 7                                        | 1 yr.                                              | 3,000,000/cc                  | 20%      | 3 mo.                             | 30,000,000 | 75%      |
| 20                  | 5                                        | 2 yr.                                              | 6,000,000/cc                  | 10%      | 4 mo.                             | 72,000,000 | 45%      |
| 24                  | 3                                        | 2 yr.                                              | 8,000,000/cc                  | 0%       | 6 mo.                             | 20,000,000 | 75%      |
| 27                  | 6                                        | 5 yr.                                              | Occas. Sperm                  | 0%       | 8 mo.                             | 39,000,000 | 65%      |
| 35                  | 2                                        | 1 yr.                                              | Occas. Sperm                  | 0%       | 5 mo.                             | 32,000,000 | 55%      |
| 38                  | 2                                        | 1 yr.                                              | 3,000,000/cc                  | 0%       | 8 mo.                             | 80,000,000 | 95%      |
| 47                  | 10                                       | 6 yr.                                              | 2,000,000/cc                  | 0%       | 4 mo.                             | 61,000,000 | 50%      |
| 51                  | 6                                        | 1½ yr.                                             | Occas. Sperm                  | 0%       | 1 mo.                             | 20,000,000 | 50%      |
| 53                  | 8                                        | 1 yr.                                              | 3,000,000/cc                  | 20%      | 1 mo.                             | 18,000,000 | 65%      |

**Table 2.** "Successes" with Conventional Technique Who Became Azoospermic by 2 Months After Original Vasovasostomy

| PATIENT No. | ORIGINAL SPERM COUNT                 |          | SUBSEQUENT SPERM COUNT | SPERM COUNT AFTER REOPERATION |          |
|-------------|--------------------------------------|----------|------------------------|-------------------------------|----------|
|             | CONCENTRATION/CC                     | MOTILITY |                        | CONCENTRATION/CC              | MOTILITY |
| 2           | 19,000,000                           | 2%       | Zero                   | 86,000,000                    | 60%      |
| 5           | "Many Motile"                        |          | Zero                   | 50,000,000                    | 70%      |
| 28          | 20,000,000                           | 50%      | Zero                   | 85,000,000                    | 80%      |
| 33          | "Sperm Seen"                         |          | Zero                   | 22,000,000                    | 50%      |
| 36          | "A Few Sperm"                        |          | Zero                   | 18,000,000                    | 45%      |
| 37          | 28,000,000                           | 60%      | Zero                   | 133,000,000                   | 98%      |
| 43          | "Motile Sperm"                       |          | Zero                   | Not Reported Yet              |          |
| 45          | "Motile Sperm in Reasonable Numbers" |          | Zero                   | 89,000,000                    | 30%      |
| 50          | 90,000,000                           | 60%      | Zero                   | 20,000,000                    | 50%      |
| 52          | "Some Sperm"                         |          | Zero                   | Not Reported Yet              |          |

was performed less than 10 years ago and those whose vasectomy was more than 10 years ago, we find that 91 per cent developed normal sperm counts after reoperation if their original vasectomy had been performed within 10 years. For those whose vasectomy had been performed over 10 years ago, only 59 per cent developed a normal count.

**Quality of Vas Fluid and Interval Since Vasectomy**

One hundred and twenty-one consecutive patients with no previous attempts at vasovasostomy were followed for up to eight months, with the quality of their seminal fluid at the time of surgery being related to subsequent sperm counts. When the vasectomy was within 10 years of the reversal, 91 per cent developed a normal sperm count within six months and 94 per cent had some sperm in the ejaculate. However, if the vasectomy had been performed over 10 years earlier, only 35 per cent obtained normal sperm counts within six months and only 47 per cent had sperm in the ejaculate at all. When the vasectomy was performed over 10 years ago, only 12 out of 26 patients had any sperm in the vas fluid at the time of surgery. Furthermore, those whose vasectomy was performed over 10 years ago and who had no sperm in the vas fluid at the time of surgery did not show sperm in the ejaculate up to six months postoperatively. If there was sperm in the vas fluid in this group, 75 per cent developed normal sperm counts.

These patients demonstrated clearly the deleterious effect of a prolonged duration of obstruction on successful return of fertility after reconstruction of the vas deferens. Therefore, any series of vasovasostomies weighted toward patients whose vasectomies were performed more recently is going to have a higher success rate no matter how crude the technique of surgery. One might surmise that nearly every anastomosis was patent since the cases in which no sperm appeared postoperatively were those in which there was no sperm on the testicular side of the obstruction preoperatively. If there were sperm in the

vas fluid preoperatively, there was a 90 per cent chance of developing a normal sperm count some time after surgery. Even if the initial sperm were degenerate and senescent, these patients had a good prognosis.

### **Dilatation of Vas and Sperm Granuloma**

The next 92 consecutive patients studied are probably the most fascinating and shed much light on the whole mechanism for retaining the potential of fertility after vasectomy.<sup>17</sup> We noted an improved quality of sperm in the vas fluid in patients who had minimal dilatation of the lumen on the testicular side and in patients who had a sperm granuloma at the site of the vasectomy. Therefore, in the next 92 patients meticulous records were kept regarding the presence and size of any sperm granuloma at the site of vasectomy, the diameter of the vas lumen, and the quality of sperm in the vas fluid at the time of surgery.

Fifty-nine out of the 184 (32 per cent) vasa examined had a sperm granuloma noted at the site of vasectomy. There were no symptoms of discomfort related to the sperm granuloma. In this group, 92 per cent had morphologically normal sperm in the vas fluid; the other 8 per cent had morphologically normal sperm as well as some degenerate forms. Thus, in the group with sperm granuloma, no vas failed to have good quality sperm in the fluid. Even when the vasectomy had been performed over 10 years ago, none of these patients had poor quality sperm in the vas fluid.

By contrast, only 7 per cent of patients with no sperm granuloma had mostly morphologically normal sperm in the vas fluid and 22 per cent had morphologically normal sperm plus degenerate sperm. A total of 26 per cent had no sperm in the vas fluid and 45 per cent had only degenerate sperm heads.

The internal diameter of the lumen on the testicular side of the vas deferens was almost always 0.75 mm or less in vasa with sperm granuloma. In patients without sperm granuloma, the internal diameter of the testicular side lumen was usually 1 mm or greater. Thus, the presence of the sperm granuloma was associated with less dilatation of the vas deferens on the testicular side of the obstruction.

In patients who had unilateral sperm granulomas, the sperm quality was satisfactory on the side with the sperm granuloma but was of much poorer quality on the opposite side. Thus, a dramatic benefit was conferred on the sperm output on the side with sperm granuloma that did not extend over to the side without granuloma. These data favor the postulate that a failure of recovery of fertility after an accurate anatomic reconnection of the vas deferens is due to the local effects of high pressure created by the vasectomy. This intravasal pressure appears to be less in patients who have sperm granulomas.

The portion of the vas deferens excised at the time of vasectomy and the site of the vas deferens involved had no correlation with sperm quality or results. Indeed, in the majority of patients in this series, the vasectomy had extended to the convoluted portion and a very large segment of vas deferens had often been excised.



The early followup on patients with sperm granuloma indicated that most of these patients developed a normal sperm count regardless of the interval since vasectomy. Among those who did not have sperm granuloma, 88 per cent developed normal sperm counts if the vasectomy occurred less than 10 years ago, but only 29 per cent developed normal sperm counts if the vasectomy occurred over 10 years prior to surgery.

#### CONCLUSIONS

Thus, the three most important factors that appeared to influence the return of fertility after vasovasostomy were (1) a meticulous microscopic technique for reanastomosis, (2) the duration of time the vas deferens has been subjected to obstruction, and (3) the presence or absence of sperm granuloma at the site of vasectomy. The importance of an accurate microsurgical technique is underlined by the 53 patients with previous failures, the majority of whom recovered fertility after microscopic reanastomosis. The importance of duration of time since the original vasectomy and the possible protective effect of a sperm granuloma demonstrate that the intravasal pressure created by the vasectomy may be one of the major problems in restoration of fertility after accurate vasovasostomy.

The epididymis can reabsorb fluid and thus withstand some of this increased intravasal pressure. Turner et al. sampled fluid by micropuncture from four areas of the rat epididymis, from the caput to the distal cauda, and documented a large resorption of water from the epididymal lumen as the seminal fluid travels toward the vas from the testes.<sup>24</sup> They did note any significant reabsorption of sperm and, in fact, noted a very significant increase in sperm concentration. They suggest that an active sodium pump drives this concentration gradient. In the majority of patients who do not have sperm granuloma, this reabsorption appears to be a major protective mechanism. However, the appearance of a sperm granuloma following vasectomy, venting this high pressure even further, may improve the prognosis in most patients for future reversibility. Certainly, in the absence of such a sperm granuloma, the duration of obstruction since vasectomy is extremely important.

#### EFFECTS OF VASECTOMY ON THE TESTIS AND EPIDIDYMIS

There is a great deal of controversy in the scientific literature about the long-term effect of vasectomy on both humans and animals. Many of the differences in experimental results are related to the use of different animal models and different techniques of vasectomy.

There is no question about the marked dilatation of the vas deferens and epididymal tubules that occurs consequent to vasectomy. This has been observed in almost every case in men coming for vasovasostomy from one year to 28 years after vasectomy. When the vasectomy

has been performed recently, though the fluid is not nearly as copious as in the usual vasovasostomy case, there is still more fluid than in the non-obstructed state. It appears, therefore, that pressure does begin to build within the vasal system after vasectomy, but the changes of dilatation and congestion are not really apparent until many months have passed.

A review of the extensive literature on the effects of vasectomy on the testis and epididymis, however, is beyond the scope of this paper.

However, it is clear that there are changes in pressure induced by the vasectomy upon the testis and epididymis that may effect subsequent restoration of fertility after accurate reanastomosis. Future studies are needed to determine whether in some patients permanent damage is done to the seminiferous tubules, or whether some sort of secondary ductular obstruction is caused by rupture and extravasation in the rete testis or epididymis.

### **Sperm Antibodies**

In addition to the clear-cut and obvious effects of pressure created by vasectomy, there has been a great deal of speculation about the role of autoantibodies to sperm in preventing subsequent restoration of fertility after an accurate vasovasostomy. Many studies have demonstrated the formation of antisperm antibodies, but most have not been able to show any association between the formation of antibodies and subsequent infertility. Antibodies to sperm may be a marker of ductal leakage induced by the pressure increase after vasectomy. Additional studies will be necessary to define the relationship, if one exists, between sperm antibodies and postvasectomy infertility.

### **Future Efforts**

It is clear that the effects of obstruction on the entire epididymal and testicular system are so vast that purely physical factors may be affecting the recovery of normal sperm production and maturation even after successful vasovasostomy. Sperm granuloma may represent a safety release valve that helps to alleviate the high buildup of pressure that would occur in the intravasal system proximal to the vasectomy site. Those patients without sperm granuloma at the vasectomy site may be more likely to have sperm extravasation and secondary obstruction in the epididymis or rete testis. Thus although the formation of sperm granuloma is slightly more likely to lead to antisperm antibody formation, it may be that its pressure-relieving effects will turn out to be more important. It is certainly clear from our clinical data that sperm granuloma provides remarkable protection from these pressure-induced changes following vasectomy. Further study on the nature of these changes are necessary.

## **SUMMARY**

In our series the overall pregnancy rate after vasovasostomy in an unselected group of early patients was 71 per cent. Recovery of fertili-

ty correlated with the return of normal sperm counts and with the quality of vas fluid on the testicular side of obstruction at the time of vasovasostomy. The three most important factors in our group influencing return of fertility after vasovasostomy were a meticulous microscopic technique for reconnection, the duration of time the vas deferens has been obstructed, and the presence or absence of a sperm granuloma at the site of vasectomy. The presence of a sperm granuloma at the site of vasectomy virtually ensured the presence of good quality sperm in the vas fluid at the time of vasovasostomy. If all three of these factors are favorable, vasectomy may be reversible for more patients.

## REFERENCES

1. Cameron, C. S.: Anastomosis of the vas deferens. *J.A.M.A.*, 127:119, 1945.
2. Derrick, F. C., Jr., Yarbrough, W., and D'Agostino, J.: Vasovasostomy: results of questionnaire of members of the American Urological Association. *J. Urol.*, 110:556, 1973.
3. Dorsey, J. W.: Anastomosis of the vas deferens to correct post vasectomy sterility. *J. Urol.*, 70:515, 1953.
4. O'Conor, V. J.: Anastomosis of the vas deferens after purposeful division for sterility. *J.A.M.A.*, 136:162, 1948.
5. Pardanani, D. S., Kothari, M. L., Pradhan, S. A., et al.: Surgical restoration of vas continuity after vasectomy: further clinical evaluation of a new operation technique. *Fertil. Steril.*, 25:319, 1974.
6. Phadke, G. M., and Phadke, A. G.: Experiences in the reanastomosis of the vas deferens. *J. Urol.*, 97:888, 1967.
7. Schmidt, S. S.: Anastomosis of the vas deferens: an experimental study. II. Successes and failures in experimental anastomosis. *J. Urol.*, 81:203, 1959.
8. Schmidt, S. S.: Anastomosis of the vas deferens: an experimental study. IV. The use of fine polyethylene tubing as a splint. *J. Urol.*, 85:838, 1961.
9. Schmidt, S. S.: Technics and complications of elective vasectomy. *Fertil. Steril.*, 17:467, 1966.
10. Silber, S. J.: Compensatory and obligatory renal growth in babies and adults. *Aust. N.Z. J. Surg.*, 44:421, 1974.
11. Silber, S. J.: Transplantation of rat kidneys with acute tubular necrosis into salt loaded and normal recipients. *Surgery*, 77:487, 1975.
12. Silber, S. J.: Growth of baby kidneys transplanted into adults. *Arch. Surg.*, 111:75, 1976.
13. Silber, S. J.: Microscopic technique for reversal of vasectomy. *Surg. Gynecol. Obstet.*, 143:630, 1976.
14. Silber, S. J.: Successful auto-transplantation of an intra-abdominal testicle to the scrotum using micro vascular anastomosis. *J. Urol.*, 115:452, 1976.
15. Silber, S. J.: Microscopic vasectomy reversal. *Fertil. Steril.*, 28:1191, 1977.
16. Silber, S. J.: Perfect anatomical reconstruction of vas deferens with a new microscopic surgical technique. *Fertil. Steril.*, 28:72, 1977.
17. Silber, S. J.: Sperm granuloma and reversibility of vasectomy. *Lancet*, 2:588, 1977.
18. Silber, S. J. (ed.): *Microsurgery*. Baltimore, Williams & Wilkins. (In press.)
19. Silber, S. J., and Crudop, J.: Kidney transplantation in inbred rats. *Am. J. Surg.*, 125:551, 1973.
20. Silber, S. J., and Crudop, J.: A three kidney rat model. *Invest. Urol.*, 11:466, 1974.
21. Silber, S. J., Galle, J., and Friend, D.: Microscopic vasovasostomy and spermatogenesis. *J. Urol.*, 117:299, 1977.
22. Silber, S. J., and Malvin, R. L.: Compensatory and obligatory renal growth in rats. *Am. J. Physiol.*, 226:114, 1974.
23. Soonawala, F. P.: Recanalization of the vas deferens. Bombay, Family Planning Association of India.
24. Turner, T. T., Hartmann, P. K., and Howards, S. S.: In vivo, sodium, potassium and sperm concentrations in the rat epididymis. *Fertil. Steril.*, 28:191, 1977.

## EDITORIAL COMMENTS

Several points made by Dr. Silber are of special interest: (1) repeat vasovasostomy often succeeds; (2) the prognosis is poor if no sperm are present in the vasa at the time of surgery; (3) a long delay between vasectomy and repair may be detrimental; and (4) a sperm granuloma may improve the prognosis.

Much still remains to be learned about the physiological sequelae of vasectomy. What do sperm antibodies really reflect? In those patent anastomoses with persistent infertility, is failure related to intrinsic testicular or epididymal pathology? Thus as Dr. Silber points out in this article, the pathophysiology of the long-term effects of vasectomy needs further evaluation.