

VASECTOMY
Immunologic and Pathophysiologic Effects
in Animals and Man

CHAPTER 21. STUDIES ON TESTICULAR BIOPSIES FROM
VASECTOMIZED MEN

Pierluigi E. Bigazzi

Department of Pathology
University of Connecticut Health Center
Farmington, Connecticut

Nancy J. Alexander

Oregon Regional Primate Research Center
Beaverton, Oregon

Sherman J. Silber

Ballas Parkway Medical Center
St. Louis, Missouri

INTRODUCTION

Despite the prevalence of vasectomy, very few reports have been published on the histopathology of the testis after this procedure in man. Kubota (1) examined testicular biopsies from 8 vasectomized men and 34 healthy male controls. Although he observed no gross abnormalities in the testes, the biopsies obtained from two subjects 3 and 7 years after surgery, showed degenerative changes of spermatocytes. Hagedorn and Davis (2) similarly studied testicular biopsies from individuals 3-7 years post-vasectomy and reported in a short abstract that Sertoli cells appeared intact and the germinal epithelium showed normal stages of spermatogenesis. However, spermatozoa were not observed adjacent to the lumen but rather in the basal part of the Sertoli cells, close to the basement membrane of the seminiferous tubules, and furthermore the Sertoli cells contained large numbers of lysosomes between the nucleus and the basement membrane. These

researchers interpreted their findings as suggestive of increased phagocytosis of spermatozoa by Sertoli cells. Finally, Derrick and his associates (3) also reported normal but probably reduced spermatogenesis after vasectomy in man. Thus all studies to date indicate continued spermatogenesis but possibly qualitative and quantitative changes.

Whether events resulting from humoral or cellular immune responses take place after vasectomy specifically in the human testis is not known. A reduction in spermatogenesis has been noted in vasectomized guinea pigs (4). Patchy lesions similar to those of allergic orchitis have been reported (5) and recently it has been shown that injection of peritoneal exudate cells from vasectomized animals to syngeneic recipients will result in transfer of the lesion (6).

Recent studies have shown marked immunopathologic changes in testes of long-term vasectomized rabbits. Testis sections from rabbits with high and persistent levels of circulating antibody reveal the presence of granular immune complex deposition around the seminiferous tubules (7-9). Elution and electron microscope studies support the hypothesis that the complexes involve sperm antigens and antibody to these antigens.

No published reports of immunopathologic studies of human material are available at present. Such investigations may help in resolving the question of the safety of vasectomy in men. Recently, we have had the opportunity to study both sera and testicular biopsies from 21 vasectomized subjects undergoing reanastomosis of the vas deferens. The preliminary results obtained in this study form the subject of our report.

METHODS

We examined the sera for antibodies to spermatozoa using the macroscopic sperm agglutination technique of Kibrick (10), the sperm immobilization technique of Isojima (11), and indirect immunofluorescence on sperm smears. The smears were prepared with fresh human spermatozoa washed three times and diluted to 60×10^6 spermatozoa/ml. They were air dried, fixed in methanol for 30 minutes and stored at -70° until used. At that time, they were incubated for 30 minutes with sera diluted 1:10, washed, incubated for 45 minutes at room temperature with fluorescein-conjugated rabbit antihuman immunoglobulin G and M. After a final rinse, the slides were mounted in buffered glycerol and read under a Zeiss epifluorescence microscope. To test for antiprotamine antibodies (SSH), slides of swollen spermheads were prepared according to Samuel *et al.* (12) and then stained as above.

Immunopathological investigations on testicular biopsies were performed independently in two laboratories. In one (N.J.A.), direct immunofluorescence was performed on cryostat sections rinsed in phosphate buffered saline (PBS) for 3 minutes, ether-95% ethanol (1:1) for 10 minutes, 95% ethanol for 20 minutes and PBS twice for 5 minutes. The sections were incubated for 45 minutes with fluorescein-conjugated antisera to human IgG, IgM, IgA, C3 and fibrinogen. They were then rinsed twice in PBS, mounted in buffered glycerol and read under a Zeiss epifluorescence microscope. In the other laboratory (P.E.B.), cryostat sections were washed in PBS for 10 minutes and then incubated for 30 minutes with fluorescein-conjugated antisera to human IgG, IgM, IgA, C3, albumin and fibrinogen. They were then washed for 30 minutes in PBS, mounted in buffered glycerol and read under a Leitz Dialux fluorescence microscope.

RESULTS AND DISCUSSION

The sera of 13 vasectomized subjects were tested by the Isojima technique with results that varied from 0.9 to 49. Only serum from one individual was markedly positive. The same sera were tested by the Kibrick procedure and 3 were found to be positive with titers from 40 to 640; the remaining sera were negative. In contrast, a greater percentage of strongly positive results were obtained with sera from another group of patients from the same medical facility, thus indicating that handling or shipping of the sera had not affected the antibody titer. The sera in the present study were also tested for antibodies by indirect immunofluorescence on human spermatozoa. Four were found to give equatorial staining for IgG. When stained for circulating IgM antisperm antibodies, 5 samples exhibited an acrosomal pattern, 5 a tail pattern, and 4 an equatorial pattern. Four sera were positive for antiprotamine (swollen spermhead) antibodies. There was no correlation between positivity in the immunofluorescence test and the Isojima and Kibrick procedures (Table 1).

In both laboratories all testicular biopsies were found to be negative for immune deposits at the level of the basement membrane of the seminiferous tubules.

Histopathological observations on hematoxylin-eosin stained sections of testicular biopsies were also performed independently in our laboratories. There was general agreement that the majority of the biopsies contained normal testicular tissue. However, 4 of the 21 subjects showed alterations in the seminiferous tubules and/or the interstitial tissue.

TABLE I. Results of Serum Antibody Levels from Vasectomized Men.

Patient No.	Years After Vasectomy	SI	SA	SSH	IgG ^a	IgM		
						Ac	T	Eq
2794	14	3.5	>640	+	+	+	-	+
3074	5	2.9	80	-	-	+	-	-
4860	8	1.8	40	-	-	-	-	+
2884	2	49.0	-	-	-	+	+	-
5000	9	1.8	-	+	-	+	+	-
3117	12	2.7	-	+	-	-	+	-
3985	22	1.8	-	+	-	-	-	-
3095	9	0.9	-	-	+	+	+	+
2695	7	3.1	-	-	+	-	+	-
2937	6	3.0	-	-	+	-	-	+
4929	15	2.2	-	-	-	-	-	-
2863	9	1.5	-	-	-	-	-	-
4317	4	0.9	-	-	-	-	-	-

^aIgG fluorescence was found only in the equatorial region in these samples.

Abbreviations: SI = sperm immobilizing antibodies; SA = sperm agglutinating antibodies; SSH = swollen sperm head antibodies; Ac = acrosome; T = tail (tip); Eq = equatorial.

Two subjects showed disruption of the germ cell layers, with thickening of the tubular basement membrane, while in the other two there was evidence of fibrosis in the interstitial tissue (Figs. 1-4). At present, we have no explanation for these observations. However, this study as well as those of other investigators suggests that some individuals may respond by exhibiting slight testicular changes and a reduction in spermiogenesis. Whether such changes are reversible is not known.

In conclusion, our studies on the testicular biopsies from 21 vasectomized subjects have given negative results as far as the presence of immune complexes in the testes is concerned. They have also confirmed that, in general, the testicular structure is not grossly altered in vasectomized subjects.

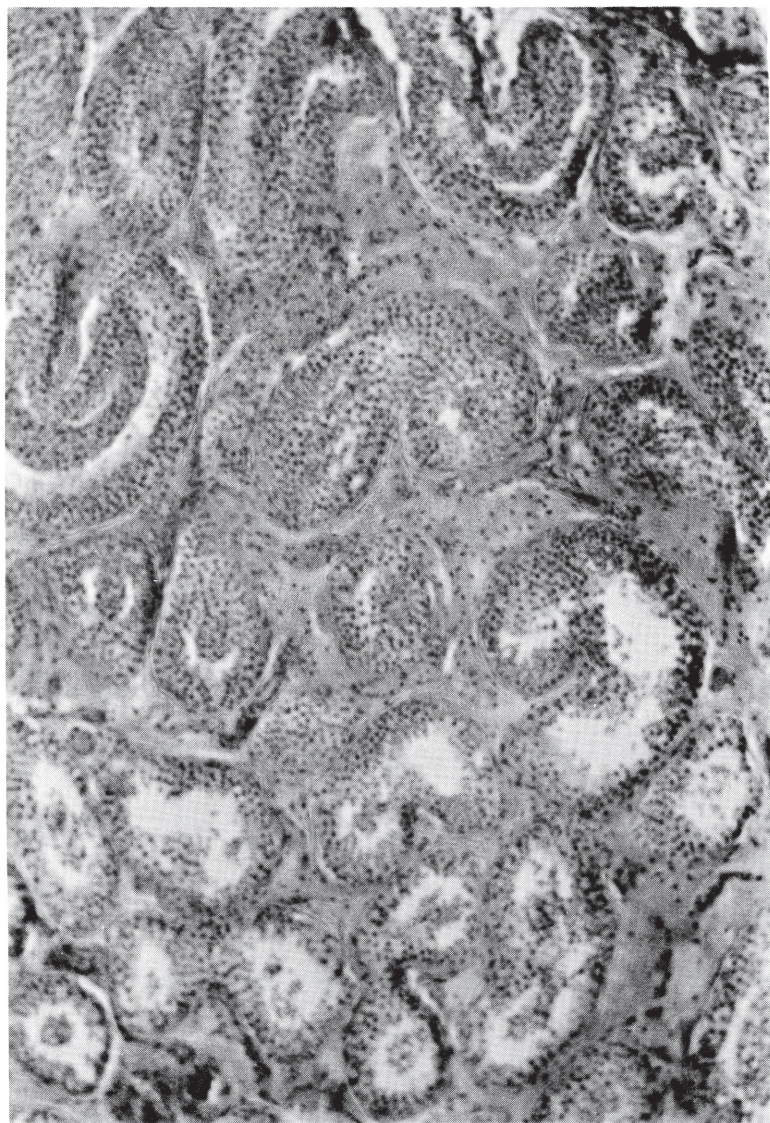


FIGURE 1. Testicular biopsy from patient 4764 (63x).

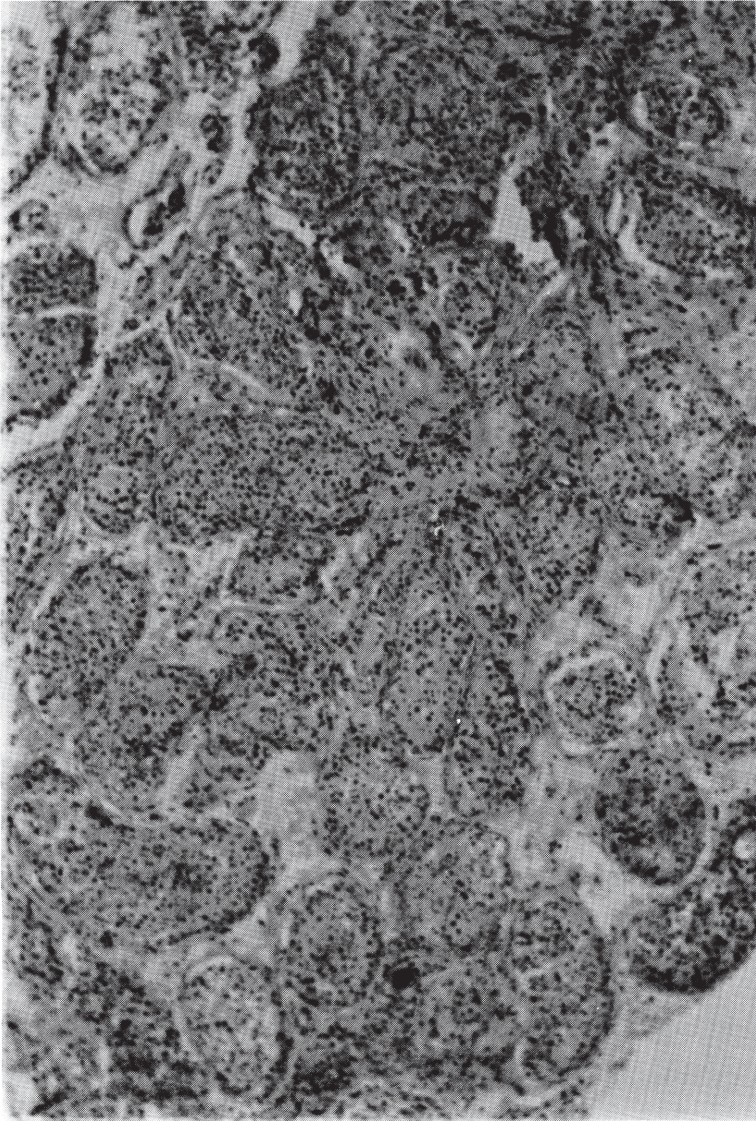


FIGURE 2. Testicular biopsy from patient 4051 (63x) .

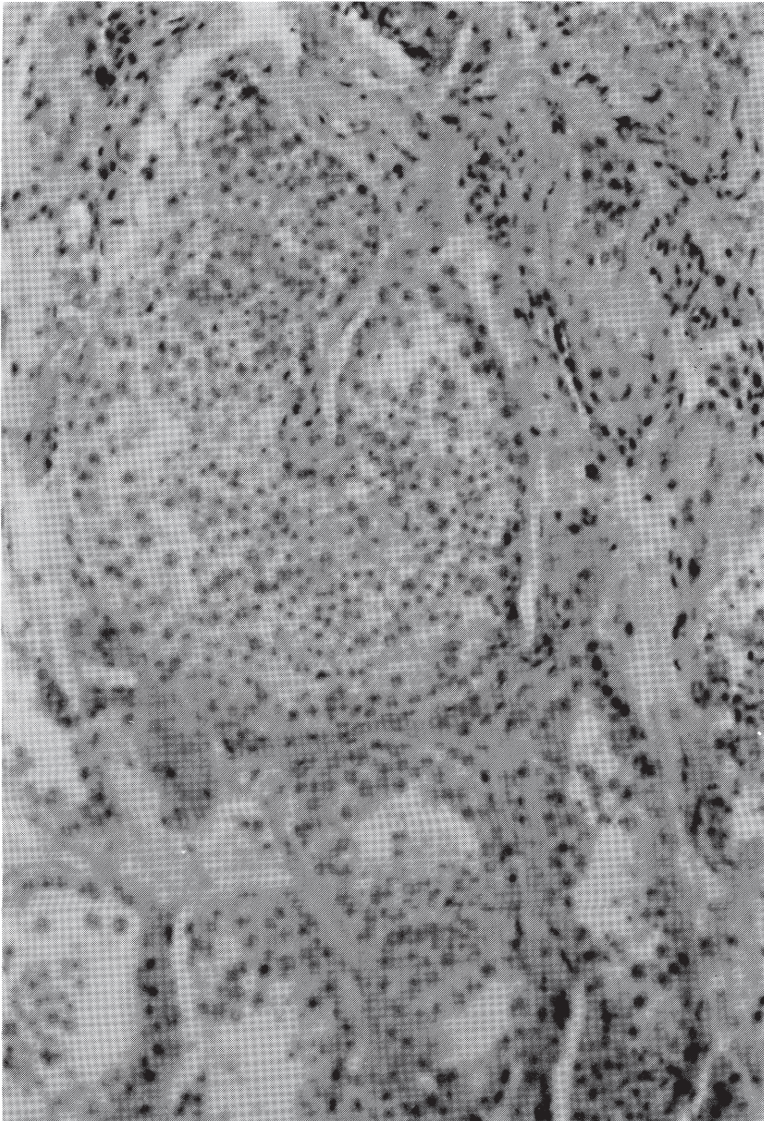


FIGURE 3. Testicular biopsy from patient 4741 (160x).

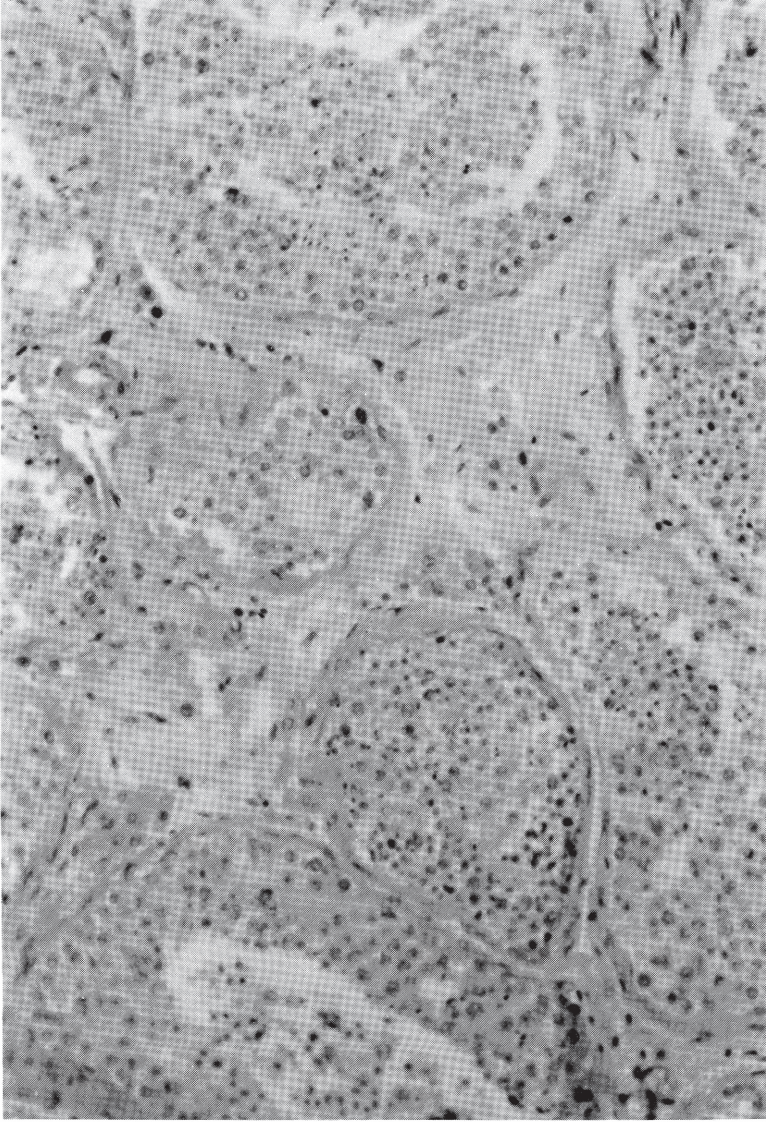


FIGURE 4. Testicular biopsy from patient 2695 (160x).

Unfortunately, we cannot exclude the possibility that our results may have been biased by the selection of the subjects investigated. As shown by the negative results obtained in the serological studies for sperm antibodies, none of our subjects had a strong autoimmune response to antigens of spermatozoa. This finding alone might explain the lack of immune-mediated damage in the testes.

REFERENCES

1. Kubota, R. Electron microscopic studies of the testis after vasectomy in rats and men. Jpn. J. Urol. 60, 373 (1969).
2. Hagedoorn, J. P. and Davis, J. E. Fine structure of the seminiferous tubules after vasectomy in man. Physiologist 17, 236 (1974).
3. Derrick, F. C., Glover, W. L., Kanjuparamban, Z., Jacobson, C. B., McDougall, M., McCowin, K., Mercer, H. D. and Rollins, L. D. Histologic changes in the seminiferous tubules after vasectomy. Fertil. Steril. 25, 649 (1974).
4. Alexander, N. J. Autoimmune hypospermatogenesis in vasectomized guinea pigs. Contraception 8, 147 (1973).
5. Tung, K. S. K. and Alexander, N. J. Immunopathologic studies on vasectomized guinea pigs. Biol. Reprod. 17, 241 (1977).
6. Tung, K. S. K. Allergic orchitis lesions are adoptively transferred from vasoligated guinea pigs to syngeneic recipients. Science 201, 833 (1978).
7. Bigazzi, P. E., Kosuda, L. L., Harnick, L. L., Brown, R. C. and Rose, N. R. Antibodies to testicular antigens in vasectomized rabbits. Clin. Immunol. Immunopathol. 5, 182 (1976).
8. Bigazzi, P. E., Kosuda, L. L., Hsu, K. C. and Andres, G. A. Immune complex orchitis in vasectomized rabbits. J. Exp. Med. 143, 382 (1976).
9. Alexander, N. J. and Tung, K. S. K. Immunological and morphological effects of vasectomy in the rabbit. Anat. Rec. 188, 339 (1977).
10. Kibrick, S., Belding, D. L. and Merrill, B. Methods for the detection of antibodies against mammalian spermatozoa. II. A gelatin agglutination test. Fertil. Steril. 3, 430 (1952).
11. Isojima, S., Li, Y. S. and Ashitaka, Y. Immunologic analysis of sperm-immobilizing factor found in sera of women with unexplained sterility. Am. J. Obstet. Gynecol. 101, 677 (1968).
12. Samuel, T., Crewe, P. R., Kolk, A. H. J., Rumke, P. R. and Barnes, R. D. Cross-reaction of antibodies present in sera of vasectomized mice with human swollen spermheads. Clin. Exp. Immunol. 25, 80 (1976).

DISCUSSION

ROSE: Since about half of vasectomized men develop sperm antibodies, how did you happen to get 12 consecutive biopsy samples from men with little or no antibody? Was it just bad luck or the fact that men who want a recanalization are poor responders to sperm antigens?

EMSLANDER: Dr. Alexander reported that the monkeys with the highest prevasectomy sperm counts developed the highest anti-sperm antibody titers. With that observation in mind, I wonder if sperm counts are available on these 12 humans and if there appears to be a similar correlation.

BIGAZZI: We do not have sperm counts of these subjects.

ZATUCHNI: In the vasectomized men showing little or no antibody formation, what was the incidence of sperm granuloma?

BIGAZZI: At present we do not know, but we are planning to obtain this and other clinical data from the urologist who provided the biopsies.

DYM: I was surprised at your interpretation of the human testicular biopsies after vasectomy. I expected to see normal histology of the testis, and indeed you reported that the biopsies that you examined were normal. However, on the slides that you presented, there were obvious major defects in spermatogenesis. I find this difficult to understand. Is the defect due to the vasectomy or the surgical biopsy technique?

BIGAZZI: In my presentation, I pointed out that biopsies from four subjects had abnormalities in the interstitial tissue and/or the seminiferous tubules. The possible causes of these abnormalities are under investigation.

HESS: Do anti-sperm antibodies develop after testicular biopsy?

BIGAZZI: This question should be addressed to Dr. Ansbacher, who has investigated this problem.

ANSBACHER: A report by Jan Friberg in the International Journal of Andrology, Vol. 1, January 1978, showed no evidence of sperm antibodies following testicular biopsy. This study was performed on about 50 men followed through three months post-biopsy (one complete spermatogenic cycle), and confirms previous data about the lack of antibody response to testicular biopsy reported by Ansbacher in Fertility and Sterility in 1975.

RUMKE: Some years ago, Hjort et al. showed that, after a testis biopsy, there may be a transient appearance of low levels of sperm antibodies.

HOWARDS: I agree with Dr. Alexander that we should not promote surgical procedures in man which encourage granuloma formation. However, it is clear that in Dr. Silber's series the pregnancy rate after vasovasostomy is higher in men who had a spermatic granuloma than men who did not.