Pregnancy After Testicular Transplant: Importance of Treating the Couple

SHERMAN J. SILBER, M.D., AND LOUIS J. RODRIGUEZ-RIGAU, M.D.

Reprinted from April 1980 Fertility and Sterility

PUBLISHED MONTHLY BY THE AMERICAN FERTILITY SOCIETY, BIRMINGHAM, ALABAMA

FERTILITY AND STERILITY
Vol. 33, No. 4, April 1980

PREGNANCY AFTER TESTICULAR TRANSPLANT: IMPORTANCE OF TREATING THE COUPLE

SHERMAN J. SILBER, M.D.*
LOUIS J. RODRIGUEZ-RIGAU, M.D.†

St. Lukes West Hospital, St. Louis, Missouri 63112, and Department of Reproductive Medicine and Biology, University of Texas Medical School at Houston, Houston, Texas 77025

CASE REPORT

The treatment of infertility usually involves evaluation of the husband by a urologist and evaluation of the wife by a gynecologist. If a "male factor" is diagnosed by the urologist, the gynecologist may sometimes delay treatment of the wife until the husband's problem has been corrected. However, preoccupation with the husband's problem, no matter how dramatic it may seem to be, can sometimes distract from treatment of the wife's contributory problem.[1, 2] It is becoming apparent that sperm counts as low as 2 million to 5 million/ml are compatible with fertility as long as sperm motility is normal and as long as the wife is properly treated.[3] In fact, approximately 10% of fertile men who elect to have a vasectomy to terminate their fertility have sperm counts below 10 million/ml.[4]

The most extreme example of male infertility is the absence of testes. After treating such a patient with a testicular transplant, the wife still did not conceive until she also was treated.[5] This case dramatically demonstrates that a high sperm count is not necessary for conception when sperm motility is adequate, and that a "biphasic" basal body temperature curve, an endometrial biopsy demonstrating "secretory endometrium," and a normal hysterosalpingogram are sometimes not sufficient to conclude that the female partner plays no role in a couple's infertility.

Received November 20, 1979; revised January 23, 1980; accepted January 28, 1980.

*St. Lukes West Hospital. To whom reprint requests should be addressed at 456 N. New Ballas Road, Suite 108, St. Louis, Mo. 63141.

†University of Texas Medical School at Houston.

The Husband. This 30-year-old man had been born without testes, while his identical twin brother had been born with two normal testes in the scrotum. The normal twin brother had already fathered three healthy children and had a sperm count averaging 40 million/ml with normal motility. The anorchic twin was receiving testosterone injections weekly to maintain normal sexual function. On May 17, 1977, the right testis of the normal twin was transplanted to the right scrotum of the anorchic twin, by means of a set of microvascular anastomoses of the spermatic artery to the deep inferior epigastric artery and of two spermatic veins to the deep and superficial inferior epigastric veins, followed by anastomosis of the vas deferens (Fig. 1). This procedure and the results were reported previously.[5] The patient's sperm count reached a range of 8 million to 14 million/ml with 30% to 50% motility within 8 months after surgery. Follicle-stimulating hormone (FSH), luteinizing hormone (LH), and testosterone levels thereafter were persistently within the normal range.

The Wife. At the time of her husband's testicular transplant the wife was 26 years old. She had no significant medical history and denied gynecologic problems in the past. Her menstrual history was essentially normal. Basal body temperature charts were biphasic, and a hysterosalpingogram was normal, demonstrating unobstructed tubes with free spillage of contrast medium. An endometrial biopsy performed premenstrually revealed secretory endometrium, indicating ovulation. Thus, what would have to be considered a standard infertility evaluation revealed no striking abnormality, yet for 2 full years following

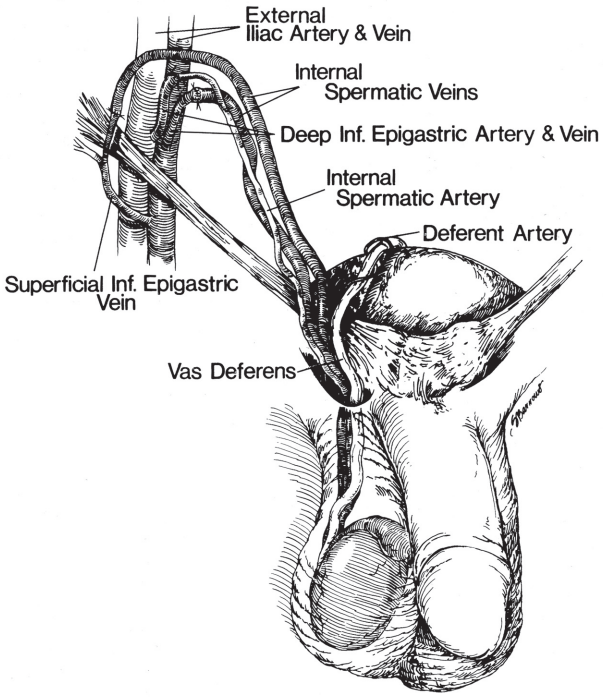

FIG. 1. Vascular anastomosis for testis transplant. (Reprinted with permission from Microsurgery, Edited by S. J. Silber. Baltimore, Williams & Wilkins Co., 1979.)

surgery on her husband, the wife failed to conceive.

A decision was made to re-evaluate her. Review of basal body temperature charts suggested that, although they were biphasic, in most cycles the luteal phase was short (8 to 11 days) and in many cycles the follicular phase was long (17 to 20 days). A postcoital test and an in vitro test of sperm penetration in cervical mucus were normal. Plasma testosterone levels, measured on day 12 of the menstrual cycle, were elevated (60.7 ng/100 ml; normal 29.3 ± 1.5 ng/100 ml). Prolactin, estradiol, LH, and FSH levels were within the normal range, but a high LH:FSH ratio was noted. The patient was placed on treatment with prednisone (7.5 mg daily). Four months later the plasma testosterone level was reduced to 30 ng/100 ml. The luteal phase length increased to 13 days, and the follicular phase length became normal as well. The patient conceived 1 month later. At the time of this writing she is approximately 5 months pregnant and the gestation has progressed thus far without complications.

DISCUSSION AND CONCLUSIONS

This case is dramatic because of the somewhat unusual treatment that was required to correct the husband's infertility. A routine evaluation of the wife initially indicated that she was "fertile." It would have been easy to attribute the lack of pregnancy for 2 years after the testicular transplant to the husband's somewhat low sperm count. However, it has been shown that sperm counts even below 5 million/ml with adequate motility can commonly result in pregnancy, and that approximately 10% of fertile men presenting for vasectomy have sperm counts under 10 million/ml.[1, 3] Thus we felt justified in re-evaluating the wife. This re-evaluation demonstrated an alteration in the normal length of the phases of the menstrual cycle.[6] Fortunately, this patient responded to treatment with normalization of testosterone levels and improvement of ovulatory function. Very shortly thereafter she conceived.

This case does not prove a phenomenon, but it serves to emphasize dramatically the interaction between both partners. Both partners must be evaluated fully no matter how one-sided the infertility problem may at first appear to be. We cannot just assign the cause of a couple's "infertility" to the male because of a relatively low sperm count without exhaustively considering the possible contribution of the wife.

ADDENDUM

The wife delivered on March 25, 1980, a normal healthy 3100 gram male infant.

REFERENCES

1. Smith KD, Rodriguez-Rigau LJ, Steinberger E: Relation between indices of semen analysis and pregnancy rate in infertile couples. Fertil Steril 28:1314, 1977
2. Sherins RJ, Brightwell D, Sternthal PM: Longitudinal analysis of semen of fertile and infertile men. In The Testis in Normal and Infertile Men, Edited by P Troen, HR Nankin. New York, Raven Press, 1977, p 473
3. Sherins RJ, Winters SJ, Wachslicht H: Studies of the role of HCG and low dose FSH in initiating spermatogenesis in hypogonadotropic men. The Endocrine Society Abstracts, Chicago, June 1977
4. Zuckerman Z, Rodriguez-Rigau LJ, Smith KD, Steinberger E: Frequency distribution of sperm counts in fertile and infertile males. Fertil Steril 28:1310, 1977
5. Silber SJ: Transplantation of a human testis for anorchia. Fertil Steril 30:181, 1978
6. Rodriguez-Rigau LJ, Smith KD, Tcholakian RK, Steinberger E: Effect of prednisone on plasma testosterone levels and on duration of phases of the menstrual cycle in hyperandrogenic women. Fertil Steril 32:408, 1979