Reversal of Vasectomy and the Treatment of Male Infertility

Role of Microsurgery, Vasoepididymostomy, and Pressure-Induced Changes of Vasectomy

*Sherman J. Silber, M.D.**

In the last 125 years, the world's population has grown from one billion to four billion. By the turn of the century, the population may very well reach 10 billion. In the face of diminishing resources, this staggering population growth is a major crisis of our time. One of the most popular and effective solutions to the problem of birth control and family planning has been vasectomy. Its only disadvantage has been its irreversibility. Until very recently, the surgical techniques for uniting the severed vas have been clumsy and fraught with failure. Furthermore, most clinicians performing vasectomy have been totally ignorant of its pressure-mediated effects on the epididymis and testis.

In order to study the problem of reversing vasectomy, we first developed a very accurate technique for microsurgically reuniting the vas deferens, thereby obtaining a dramatic improvement in postoperative semen analysis and pregnancy rate. Indeed, 88 per cent of patients who had undergone previously unsuccessful operations by competent clinicians for vasectomy reversal developed normal semen parameters after microsurgical reoperation. Seventy-one per cent of their wives achieved pregnancy. Once we had removed the artifact of a sloppy anastomosis, we were able to devote careful study to the other factors related to the secondary effects of the vasectomy itself and influencing the likelihood of recovering fertility. Much of this data has already been published (see Figs. 1 and 2).[6-13]

We will first discuss the pressure-mediated effects of vasectomy on the epididymis and the resolution of this problem through microsurgery of the epididymis. We will then discuss how the technique of vasectomy itself may be modified to limit these pressure effects to make vasectomy

*St. Luke's Hospital West, St. Louis, Missouri

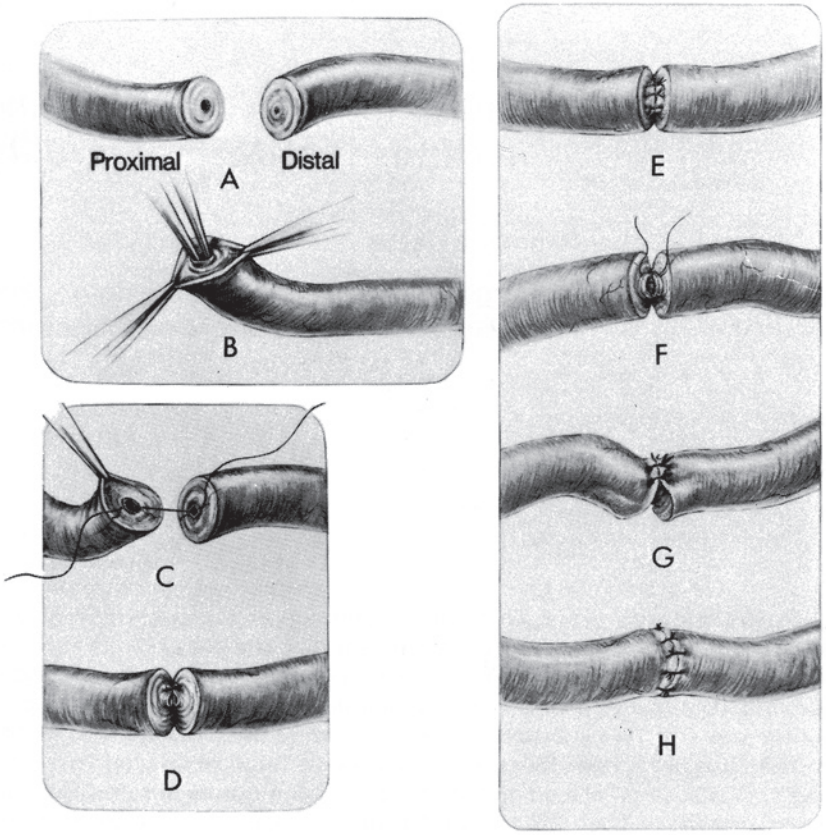

Figure 1. *A* through *H*, Diagram of the microsurgical technique for reanastomosis of the vas deferens in a straight region. (*From* Silber, S.: Microsurgery. Baltimore, Williams and Wilkins Co., 1979, with permission.)

more reversible. Finally we will consider how this new understanding has transformed surgical approaches to men with obstruction not caused by vasectomy.

The basic assumption underlying our work is an accurate microsurgical anastomosis, thus avoiding the artifact of a sloppy reconnection. Our large series of patients with poor sperm counts and demonstrable infertility after conventional vasovasostomy, who subsequently recovered fertility after microsurgical reoperation, indicates that we have progressed beyond the stage at which we have to prove that an accurate anastomosis is a basic requirement for consistent success with vasectomy reversal. Rather, this article will dwell on the more sophisticated problems that must be resolved once the microsurgical techniques for vas reanastomosis have been mastered.

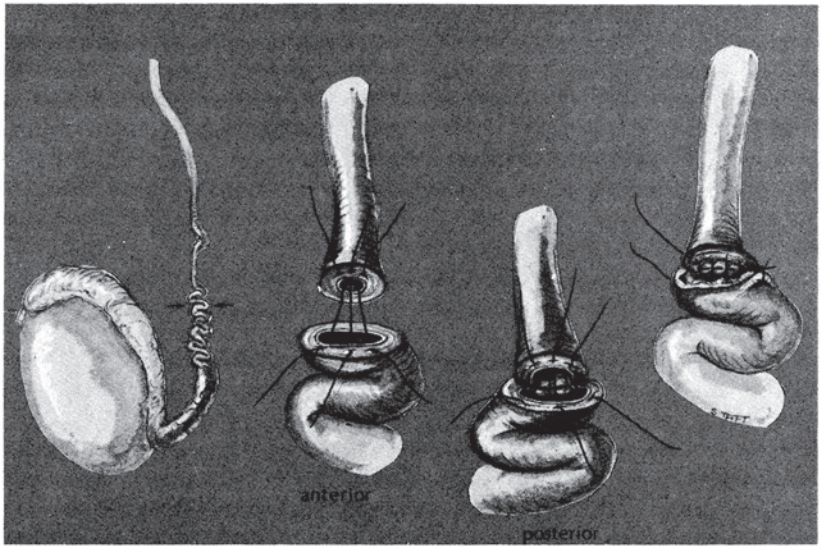

Figure 2. Diagram of the microsurgical technique for reanastomosis of the vas deferens in a convoluted region. (*From* Silber, S.: Microsurgery. Baltimore, Williams and Wilkins Co., 1979, with permission.)

THE EFFECTS OF INCREASED PRESSURE AFTER VASECTOMY

After vasectomy, increase in pressure is transmitted to the epididymis, causing relatively massive dilatation and distention. The vast majority of physicians who perform millions of vasectomies each year have been totally unaware of this pressure build-up. Because vasectomy is essentially a painless and symptom-free condition, urologists have long been unaware of the rather obvious physiologic changes that take place in humans as a result of vasectomy and that profoundly affect reversibility. Undue attention has been directed toward the question of sperm antibodies, a phenomenon which has not yet been demonstrated to affect recovery of fertility, whereas virtually no attention has been given the obvious micromechanical, pressure-induced changes that occur following all vasectomies. In over 1000 vasovasostomies performed under an operating microscope, we have always observed some degree of dilatation of the lumen of the vas deferens (which often cannot be appreciated with the naked eye) as well as congestion of the epididymis with dilatation of the epididymal tubule.

A great deal of fluid is secreted by the testis into the epididymis. The majority of this fluid is reabsorbed by the epididymis. Despite this reabsorption of testicular fluid by the epididymis, every patient who is vasectomized develops epididymal dilatation and distention. Vas ligation results in epididymal distention only; there is no discernible effect upon the testis.[1-5,14-17]

However, these pressure changes are reduced when a sperm granuloma is present at the vasectomy site. Furthermore, the presence of a sperm granuloma at the vasectomy site virtually guarantees sperm of good quality in the vas fluid. When a sperm granuloma is not evident at the vasectomy site, the sperm quality is frequently impaired, or sperm may be absent. If a sperm granuloma is present on only one side, sperm may be absent on the side without a granuloma. Without exception however, sperm will be present in the vas fluid on the side of the sperm granuloma. Moreover, in the presence of a sperm granuloma, the vas lumen is rarely dilated to more than ¾ mm in diameter, whereas when a sperm granuloma is absent, the vas lumen is usually dilated to 1.0 mm or more in diameter. Thus, a sperm granuloma provides continuous leakage of and subsequent reabsorption of vas fluid, serving as a safety valve by decompressing the vas and preventing the build-up of excessive pressure.

The likelihood of finding good quality sperm in the vas fluid at the time of vasovasostomy is diminished the greater the lapse of time between the original vasectomy and its reversal. The best results with vasovasostomy are obtained when good quality sperm are seen in the vas fluid at the time of vasovasostomy. The worst results are obtained in patients who have no sperm in the vas fluid at the time of vasovasostomy.

The question that remains is how the increase in pressure following vasectomy decreases the likelihood of a successful recovery of fertility after vasovasostomy. Until we began to perform microsurgical epididymal explorations, it was unclear how the vas fluid could be devoid of sperm despite normal spermatogenesis. The discovery that secondary epididymal obstruction is the cause of failure in these patients allowed us to develop new microsurgical techniques for vasoepididymostomy.

The lapse of time between vasectomy and its reversal correlates with the likelihood of epididymal "blowouts." In patients in whom vasectomy was performed within one year of the vasectomy reversal, we consistently noted good quality sperm in the vas fluid, as well as the development of normal semen parameters postoperatively. (In these patients, the request for a reversal was usually prompted by a crib death.) In contrast, when the vasectomy was performed more than 10 years prior to reversal, 50 per cent of the patients failed to demonstrate any sperm in the vas fluid on either side at the time of vasovasostomy. Postoperatively, this subgroup of patients remained azoospermic. When the vasectomy was performed within 10 years of the reversal, even when sperm was present only unilaterally, the patient still recovered a normal sperm count because the other side did have sperm. Thus, the time that has elapsed since vasectomy is one important factor influencing the likelihood of a successful reversal.

Since testicular biopsy is always normal even when no sperm are found in the vas fluid, and since the patient remains azoospermic after vasovasostomy, we decided to look more closely at the epididymis. Whenever there was no sperm in the vas fluid, the epididymis had blowouts with extravasation of sperm from the epididymal tubule into the interstitium, causing secondary obstruction. In over 80 per cent of the

patients, this epididymal disruption from pressure-induced blowouts occurred at the junction of the corpus and the tail of the epididymis, usually at the point at which the relatively muscular caudal epididymal tubule thins out to form the very delicate tubule of the corpus. In some cases, however, disruptions were found farther up the corpus epididymis or in the head of the epididymis. In every case in which sperm were absent in the vas fluid, we were able to locate a level in the epididymis (even up to the vasa afferentia) where normal sperm were found in the fluid.

These secondary epididymal obstructions are not easily observed with the operating microscope. Only by transecting the epididymis serially (like a sausage) could the specific focal areas of epididymal sperm granuloma and secondary obstruction be discovered. Viewing the epididymis grossly rarely reveals any useful information, except for the fact that, as with any vasectomized patient, there is epididymal dilatation. However, to the naked eye, this dilatation appeared no different in patients who had secondary epididymal disruption than in patients who did not.

Thus, we conclude that the secondary effects of the build-up of pressure on the epididymis after vasectomy can prevent recovery of fertility even after an accurate vasovasostomy. The longer the duration of time since vasectomy and the greater the increase in pressure, the greater is the likelihood of epididymal extravasation and secondary obstruction. The presence of sperm granuloma at the vasectomy site, indicating continual leakage and reabsorption, eliminates the risk of an epididymal blowout.

MICROSCOPIC VASOEPIDIDYMOSTOMY: SPECIFIC MICROANASTOMOSIS TO THE EPIDIDYMAL TUBULE

We now realize that in the special cases in which sperm are absent from the vas fluid or in which fertility is not recovered following a perfect reanastomosis of the vas, by-pass of the area of the secondary epididymal obstruction may prove to be successful in restoring fertility. In the past, most conventional techniques of vasoepididymostomy yielded miserable success rates of between 2 and 10 per cent, which were largely attributable to the tiny and delicate nature of the epididymal tubule. The basic fallacy in the conventional approach to vasoepididymostomy is that if one merely makes a slice in the epididymal tunic, multiple tubules will be present, all of which will be oozing sperm. However, the epididymis is actually one coiled tube, 20 feet in length. No matter how large an incision one makes longitudinally in the epididymal tunic, only one tubule will be truly leaking the sperm fluid. Without well-controlled microscopic observation, though, the sperm fluid appears to well up from all of the cut tubules in the epididymis. The only rational surgical approach is not simply to suture the vas deferens to the epididymal tunic, but rather to suture the inner lumen of the vas deferens directly to the one cut epididymal tubule that is leaking the sperm fluid (Fig. 3).

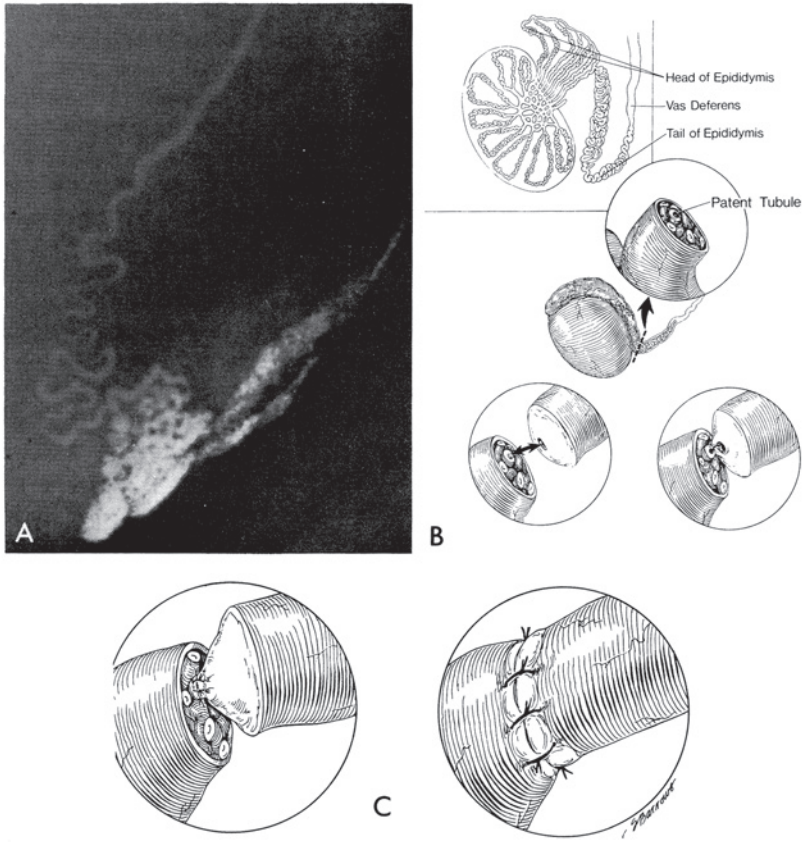

Figure 3. *A*, Radiologic anatomy of epididymal tubule. *B* and *C*, Microsurgical technique for vasoepididymostomy. (*From* Silber, S.: Microsurgery. Baltimore, Williams and Wilkins Co., 1979, with permission.)

Conventional gross vasoepididymostomy is a very crude operation, relying upon the potential formation of a sperm fistula. Using a microsurgical technique which is far more delicate than vasovasostomy, we are now able to anastomose the inner lumen of the vas deferens directly to the epididymal tubule. Thus, instead of merely hoping for the formation of a sperm fistula, we are creating an accurate anastomosis that by-passes the epididymal obstruction. The technique involves serial sectioning of the epididymis until we reach a level proximal to the obstruction where good quality sperm is found leaking from the epididymal tubule (Fig. 3).

When one first observes the transversely sectioned epididymis, there may appear to be 8 to 10 cut tubules, but of course, only one of these tubules is actually leaking sperm. The other openings are merely cut ends of this one convoluted tubule whose continuity with the proximal portion of the tubule has been severed. Thus, if one observes closely under the

operating microscope, the fluid can be seen to emerge from only one of these tubules—the one that is specifically anastomosed to the inner lumen of the vas deferens. The outer muscularis of the vas deferens is then sutured to the epididymal tunic for support.

The introduction of an operating microscope is not the only important feature of our approach to vasoepididymostomy. If we were to make a longitudinal slit in the epididymis in the traditional fashion, even an operating microscope would not allow us to identify the specific tubule to which the vas lumen should be anastomosed. In fact, it is rather irrational to make a longitudinal slit since the aim is to make an approach proximal to the level of the epididymal obstruction but to conserve as much epididymal length as possible. Thus, it makes more sense to section the epididymis serially, beginning at the caudal region proximally and continuing until sperm-laden epididymal fluid is found. If a longitudinal incision were made, it would be difficult to locate this point.

This operation is extraordinarily delicate. Unlike microscopic vasovasostomy, vasoepididymostomy requires more than just laboratory practice. It requires a great deal of experience with all kinds of microsurgical techniques. If a vasectomy reversal fails, it can always be performed again with a more accurate technique. But if a vasoepididymostomy fails, the subsequent scarring around this delicate structure makes later operations extraordinarily difficult.

About 80 per cent of our patients who have undergone bilateral vasoepididymostomy have demonstrated normal semen analysis. When the obstruction was in the distal corpus, motility usually returned to normal quickly in most cases. When the vasoepididymostomy had to be performed in the proximal regions of the corpus or in the head of the epididymis, motility did not return to normal initially. However, after prolonged follow-up (two years), these patients eventually developed normal motility also.

Thus, we now have a method for successfully reversing vasectomy even in patients who otherwise have a poor prognosis as a result of the pressure damage created by the vasectomy. However, this technique is very difficult and should not be attempted casually by the average urologist. It is more reasonable to perform the initial vasectomy in such a way as to minimize this pressure-mediated damage.

THE VASECTOMY TECHNIQUE WITH THE GREATEST LIKELIHOOD OF REVERSIBILITY

Sperm granuloma (with subsequent spontaneous recanalization) has classically been considered to be a complication of vasectomy.[5] Yet if spontaneous recanalization does not occur, the formation of a sperm granuloma at the vasectomy site may be beneficial in that it reduces the amount of pressure in the epididymis and eliminates the likelihood of an eventual epididymal blowout. When a cautery technique is employed to seal the vas at the time of vasectomy, the incidence of sperm granuloma is around 1 per cent, and recanalization is rare. On the other hand, when

ligature techniques are used for sealing the vas deferens, sperm granulomas will form in up to 30 per cent of cases, and the spontaneous recanalization rate is about 1 to 2 per cent. Spontaneous recanalization occurs when sperm leak out through the cut testicular end of the vas deferens and swim through the connective tissue, grinding a pathway to the other side. Most spontaneous recanalizations result in a low sperm count and poor motility. Eventually, such recanalization may scar down completely, subsequently causing azoospermia. However, occasionally, spontaneous recanalization will result in permanently restored fertility. Thus, the formation of a sperm granuloma at the vasectomy site, though desirable for later reversibility, cannot be taken lightly unless there can be some assurance that spontaneous recanalization will not occur.

A great deal of emotionalism has clouded our feelings about sperm granulomas, however. If vasectomy is to be performed, the physician must accept the inevitability of inducing sperm granulomas in virtually every patient. If a sperm granuloma does not form at the vasectomy site, it will certainly form eventually in the epididymis at the site of rupture of the epididymal tubule caused by the build-up of pressure. It is simply a question of the preferred site for the sperm granuloma—at the vasectomy site or in the epididymis. For the purposes of making vasectomy a reversible procedure, it would be much wiser to have the sperm granuloma form at the vasectomy site.

In determining whether pain is caused by such a sperm granuloma, we can look objectively at more than 1000 men who have undergone vasectomy one month to 28 years ago, and who have subsequently presented for vasectomy reversal. Usually, we have not found a sperm granuloma to be a source of discomfort for these patients. In fact, patients with a sperm granuloma were less likely to have epididymal tenderness than patients who had no sperm granuloma at the vasectomy site. Furthermore, in patients with a unilateral sperm granuloma, no epididymal tenderness was elicited on the side with the sperm granuloma, whereas epididymal tenderness on the side without the sperm granuloma was frequently present. Oddly enough, an epididymal blowout, discovered at the time of vasectomy reversal, was not a source of much pain either. Patients with the most aggravating epididymal tenderness usually did not have an epididymal blowout. The pressure build-up within the epididymis appears to cause most of the mild intermittent orchialgia that sometimes affects postvasectomy patients.

Of 10 patients who were referred to us because of persistent discomfort many years after initial vasectomy and who did not wish to be fertile again, two had a somewhat tender sperm granuloma. The other eight had no sperm granuloma, but had marked epididymal tenderness. After performing a vasovasostomy on these eight patients to relieve the pressure, the symptoms of discomfort and the epididymal tenderness regressed.[5]

Thus, it would be foolish for us to suppose that one can perform a vasectomy without the risk of some scrotal discomfort in a small percentage of patients. However, a sperm granuloma at the vasectomy site does not cause any increased risk of scrotal discomfort. Furthermore, it

ensures the continued integrity of the epididymis which makes reversibility much more likely.

One method of vasectomy that is designed to encourage the formation of a sperm granuloma and yet minimize the risk of spontaneous recanalization has been performed in more than 750 patients by Shapiro.[5] Nothing is done to the testicular cut end of the vas deferens at the time of vasectomy. Rather, it is allowed to leak freely into the scrotal tissue. In an early group of his patients, Shapiro sealed the lumen on the abdominal side with hot wire cautery (vasector). In a subsequent, larger group of patients, he used a hemoclip on the abdominal lumen along with fascial interposition. Three per cent of his patients failed to form a sperm granuloma. All of the others, however, formed a nontender sperm granuloma which never exceeded a diameter of 4.0 mm. None of the granulomas was tender and none of them required any surgical treatment. Thus, Shapiro is at a loss to explain why Schmidt reports that almost 50 per cent of patients with sperm granuloma after vasectomy have such severe and persistent pain that they require surgical intervention.[5]

The unsettling aspect of Shapiro's work, however, is that in the first group of patients in whom the abdominal lumen was treated with hot wire cautery, 7 per cent had spontaneous recanalization. In the second group of over 500 patients who had a hemoclip applied to the abdominal end of the cut vas deferens and who also underwent fascial interposition, recanalization never occurred. This research is very encouraging but further studies are needed to determine the simplest method for sealing the abdominal side of the vas only, with no recanalization.

Despite the greater reversibility of open-ended vasectomy, there is no doubt that the prevention of spontaneous recanalization by proper treatment of the abdominal side of the cut vas deferens is essential before this procedure can be recommended. Yet it is clear that this problem should be rather easily resolved and that answers may be available in the next year or so. Presently, instead of using the standard hot wire length of 0.5 cm, we have persuaded the manufacturer (Concept, of Clearwater, Florida) to make a hot wire that is 1.5 cm in length. With this simple change in our technique, we have thus far avoided any recanalizations. "Open-ended" vasectomy, therefore, seems to be the ideal approach to ensuring ease of reversibility, and with the longer "vasector" unit that is currently available, spontaneous recanalization is not likely to be a problem.

CONCLUSION

Any outcry against sperm granuloma, whether at the vasectomy site or in the epididymis, is really an uninformed indictment of vasectomy itself, since the formation of sperm granuloma is an inevitable and unavoidable consequence of all vasectomies. Furthermore, a small percentage of vasectomized men are going to experience some pain no matter what technique is used and whether or not a sperm granuloma

forms at the vasectomy site. The symptoms are rarely more than just a minor nuisance, and they are usually transient.

Although we certainly do not recommend vasectomy for a man who wishes to have more children, the death of a child or wife may change his view radically. It is, therefore, inhumane to disregard the possibility of future reversibility of *any* vasectomy we perform.

REFERENCES

1. Bedford, J.M.: Adaptations of the male reproductive tract and the fate of spermatozoa following vasectomy in the rabbit, rhesus monkey, hamster and rat. Biol. Reprod., *145:*118, 1976.
2. Neaves, W.B.: Permeability of Sertoli. Cell tight junctions to lanthanum after ligation of ductus deferens and ductuli efferentes. J. Cell Biol., *59:*559, 1973.
3. Pardanani, D.S., Patil, N.A., and Pawar, H.N.: Some gross observations of the epididymis following vasectomy. Fertil. Steril., *27:*267, 1976.
4. Setchell, B.P.: The secretion of fluid by the testes. Res. Reprod., *3:*1, 1971.
5. Shapiro, E.I., and Silber, S.J.: Open-ended vasectomy, sperm granuloma, and post-vasectomy orchialgia. Fertil. Steril., *32:*546, 1979.
6. Silber, S.J.: Epididymal extravasation after vasectomy as cause of failure for vasectomy reversal. Fertil. Steril., *31:*309–315, 1979.
7. Silber, S.J.: Microscopic vasectomy reversal. Fertil. Steril., *28:*1191, 1977.
8. Silber, S.J.: Microscopic vasoepididymostomy: Specific microanastomosis to the epididymal tubule. Fertil Steril., *30:*565, 1978.
9. Silber, S.J.: Perfect anatomical reconstruction of vas deferens with a new microscopic surgical technique. Fertil. Steril., *28:*72, 1977.
10. Silber, S.J.: Vasectomy and its microsurgical reversal. UROL. CLIN. NORTH AM., *5:*573, 1978.
11. Silber, S.J.: Vasectomy and vasectomy reversal. Fertil. Steril., *29:*125, 1978.
12. Silber, S.J., and Cohen, R.: A letter to the editor. Fertil. Steril., *31:*90, 1979.
13. Silber, S.J., and Cohen, R.: Normal intrauterine pregnancy after reversal of tubal sterilization in the wife and vasectomy in the husband. Fertil. Steril., *30:*606, 1978.
14. Smith, G.: The effects of ligation of the vasa efferentia and vasectomy on testicular function in the adult rat. J. Endocrinol., *23:*385, 1962.
15. Turner, T.T., Hartmann, P.K., and Howards, S.S.: In vivo sodium, potassium and sperm concentrations in the rat epididymis. Fertil. Steril., *28:*191, 1977.
16. Van Wagenen, G.: Changes in the testes of the rat following ligation of the ductuli efferenti. Anat. Rec., *29:*399, 1925.
17. Van Wagenen, G.: Degeneration of germinal epithelium in the testes of the rat as a result of efferent duct ligation. Anat. Rec., *27:*189, 1924.

456 North New Ballas Road
St. Louis, Missouri 63141