Intracytoplasmic sperm injection today: a personal review

Sherman J.Silber

Infertility Center of St Louis, St Luke's Hospital, 224 South Woods Mill Road, St Louis, MO 63017, USA

There no longer seem to be any categories of male factor infertility that cannot be treated with intracytoplasmic sperm injection (ICSI). Even for men with azoospermia caused either by obstruction or by germinal failure, ICSI may be performed successfully. The only failures will be in azoospermic men who have neither spermatozoa nor spermatids retrievable from the testis, but these men comprise a small percentage of the cases with severe male factor. The source of the spermatozoa and the cause of the sperm defect appear to have no effect on the success of the procedure, whether the spermatozoon is epididymal, fresh or frozen, testicular, ejaculated, or from the testicles of men with severe defects in spermatogenesis. Maturation arrest, Sertoli cell-only, cryptorchidism, chemotherapy and mumps do not appear to have a major impact on the pregnancy rate. Of all the factors studied in couples where the male is severely infertile or azoospermic, the only factor that seems to matter (as long as spermatozoa are retrieved) is the age of the wife and, to a considerably lesser extent, her ovarian reserve. Extensive genetic and paediatric follow-up studies of ICSI pregnancies have revealed no increased risk of congenital malformation (2.6%), no increased risk of de-novo autosomal abnormalities, and a 1.0% risk of sex chromosomal abnormalities. These results are very reassuring, but point to the need for careful counselling of couples with male infertility.

Key words: azoospermia/genetics/ICSI/review/update

Progress of ICSI since 1992

Since the publication of the first papers on the use of intracytoplasmic sperm injection (ICSI) for oligozoospermia in 1992 and 1993, an intense flurry of scientific effort has been dedicated to extending its application to virtually every type of male infertility (Palermo *et al.*, 1992; Van Steirteghem *et al.*, 1993; Silber, 1995; Silber *et al.*, 1995a). The first extension came when Nagy *et al.* (1995a) confirmed that the most severe cases of oligoasthenoteratozoospermia produced the same pregnancy rates as mild cases of male factor infertility, which were no different from those of men with normal spermatozoa undergoing conventional in-vitro fertilization (IVF). Liu *et al.* (1994a) then demonstrated that the way in which the spermatozoa are pre-treated prior to ICSI is immaterial, and that any method for aspirating the spermatozoa into an injection pipette and transferring them into the oocytes is adequate. Liu *et al.* (1995) also reported that fertilization failure was always related either to poor egg quality or to sperm non-viability. It appeared that neither the most severe morphological defect, nor the most severe motility defect, nor the tiniest number of spermatozoa in the ejaculate ('pseudoazoospermia'), had any negative effect on the pregnancy rate with ICSI (see Tables I and II). Only absolute immotility of ejaculated or epididymal spermatozoa lowered the fertilization rate, and this was found to be not due to the immotility of the spermatozoon, but rather to its non-viability. Completely non-motile spermatozoa which were viable were still capable of normal fertilization and pregnancy rates (see Figure 1).

ICSI then took another leap forward with the

 © European Society for Human Reproduction & Embryology

Table I. Result of intracytoplasmic sperm injection (ICSI) using ejaculated spermatozoa. Results are categorized according to sperm quality

	No. of cycles	2 PN (%)	Transfer (%)	Clinical pregnancies (%)
Sperm count (total)				
'0'	57	58	86	25
>0 to 1 × 10^6	97	64	96	26
>1 to 5 × 10^6	128	70	96	22
>5 × 10^6	684	71	93	30
Motility (%)				
0[a]	12	10	42	0
0	54	60	87	13
>0 to 5	19	68	100	32
>5 to 50	479	70	88	31
>50	337	74	95	26
Morphology				
0	48	68	88	31
>1 to 3	125	70	96	33
>4 to 13	307	71	94	26
>14	203	75	95	29

[a]Nagy *et al.* (1995a).
2 PN = oocytes that had two pronuclei.

Table II. Pregnancy rate following intracytoplasmic sperm injection (ICSI) from October 1992 through December 1994. From Liu *et al.* (1995)

In a total of 2732 cycles, 71% had 2 PN and 964 (36%) clinical pregnancies were achieved
Failed fertilization occurred in 29 (1%) cycles (28 couples)
Of 26 couples with failed fertilization who underwent repeat ICSI, 22 (85%) achieved fertilization in subsequent cycles

development of sperm aspiration and extraction techniques which allowed couples in whom the male was absolutely azoospermic to have pregnancy rates no different from those in whom the male had a normal sperm count (Nagy *et al.*, 1995b; Silber *et al.*, 1995b). The first successful attempts at sperm aspiration combined with ICSI were reported by Silber *et al.* and Tournaye *et al.* in 1994. Conventional IVF with aspirated epididymal spermatozoa yielded a pregnancy rate of only 9% and a delivery rate of only 4.5%, whereas ICSI with aspirated epididymal spermatozoa in men with congenital absence of the vas deferens (CAVD) yielded a pregnancy rate of 47% and a delivery rate of 33%. Furthermore, there was no difference in pregnancy rate with epididymal spermatozoa retrieved for any cause of obstruction, whether it was failed vasoepididymostomy, CAVD, or simply irreparable obstruction (Silber *et al.*, 1995c).

However, this breakthrough for men with CAVD brought with it a serious problem. It was soon discovered that CAVD is caused by mutations on the cystic fibrosis transmembrane conductance regular gene (*CFTR*) located on chromosome 7. Although now this is taken for granted, in 1992 it was a startling discovery (Dumur *et al.*, 1990; Silber *et al.*, 1991; Anguiano *et al.*, 1992). This discovery meant that all patients and their wives undergoing sperm aspiration with ICSI for CAVD required careful genetic screening for cystic fibrosis, and if the wife was a carrier (4% risk of carrier status in the general population), then the embryos should undergo preimplantation genetic diagnosis using polymerase chain reaction, so that only healthy embryos would be replaced. The first case of successful preimplantation embryo biopsy for cystic fibrosis, on the embryo of a man who had undergone microsurgical epididymal sperm aspiration (MESA) and ICSI for CAVD, was reported by Liu *et al.* (1994b) using the techniques pioneered by Handyside *et al.* (1993). The use of MESA and ICSI for CAVD led to intense molecular study of the genetic mystery of how the condition of CAVD is transmitted via defects in the cystic fibrosis gene (Chillon *et al.*, 1995; Silber *et al.*, 1995c).

Soon after the MESA–ICSI procedure was developed in 1994, it was discovered that testicular spermatozoa could fertilize as efficiently as ejaculated spermatozoa and also result in normal pregnancies (Schoysman *et al.*, 1993; Devroey *et al.*, 1995; Silber *et al.*, 1995d). This procedure was coined testicular sperm extraction (TESE). TESE truly revolutionized the treatment of infertile couples with azoospermia. The development of TESE meant that even patients with zero motility of the epididymal spermatozoa or of ejaculated spermatozoa, or even men with no epididymis could still have their own genetic child, so long as there was normal spermatogenesis. It also meant that surgeons with limited microsurgical skill could easily perform a testicle biopsy, enabling the

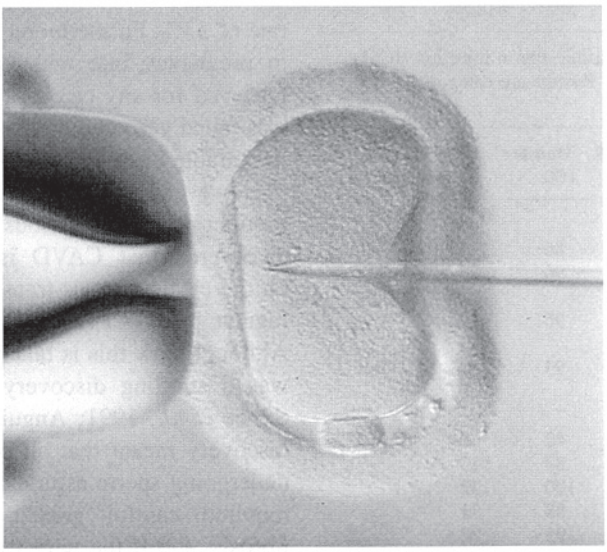

Figure 1. ICSI (intracytoplasmic sperm injection).

retrieved spermatozoa to be used for ICSI without the need for the microsurgical expertise required to perform a conventional MESA procedure.

It was also demonstrated that epididymal spermatozoa, despite fairly weak motility, could be frozen and, after thawing, yield pregnancy rates no different from those obtained with freshly retrieved epididymal spermatozoa (Devroey *et al.*, 1994). This meant that men with obstructive azoospermia could undergo a microsurgical reconstruction, without the need to have the wife prepared for simultaneous IVF. Spermatozoa retrieved from the epididymis at the time of the vasoepididymostomy could be frozen and stored. If the vasoepididymostomy proved to be unsuccessful (10% of cases), the frozen stored epididymal spermatozoa could serve as back-up to be used for any number of future ICSI procedures without the husband having to undergo further invasive surgery or aspirations (Silber, 1989a,b). Because of the remarkable success with the freezing of very poor quality epididymal spermatozoa for subsequent ICSI, couples did not have to time the MESA exactly with the wife's egg retrieval, and in fact, the wife did not have to go through any egg retrieval procedures unless the vasovasostomy or vasoepididymostomy procedure proved to have failed. Then, at any later date, at the couple's convenience, they could undergo ICSI with the frozen stored spermatozoa. This also meant that men about to undergo chemotherapy and/or radiotherapy for cancer could have a single ejaculate frozen, causing no delay in treatment of the cancer, and this one ejaculate would be sufficient for almost an infinite number of IVF–ICSI cycles.

Finally, in the majority of cases of patients with testicular failure (caused either by maturation arrest, Sertoli cell-only syndrome, cryptorchid testicular atrophy, post-chemotherapy azoospermia, or even Klinefelter's syndrome), a very tiny number of spermatozoa or spermatids can usually be extracted from extensive biopsies of the testicle and utilized for ICSI (Devroey *et al.*, 1995; Silber, 1995; Silber *et al.*, 1995a,d, 1996). This surprising ability of men who appear to produce no spermatozoa whatsoever to have their own genetic child developed from application of basic studies in quantitative analysis of testicle biopsy begun by Steinberger and Zuckerman and continued by Silber and Rodriguez-Rigau (Steinberger and Tjioe, 1968; Zuckerman *et al.*, 1978; Silber and Rodriguez-Rigau, 1981). These early studies of the kinetics of spermatogenesis in the testicle demonstrated that often a tiny amount of spermatogenesis was present if one examined quantitatively and carefully the testicle biopsy of men who were azoospermic from non-obstructive testicular failure. However, the significance of this 'threshold' phe-

nomenon was not appreciated until the era of ICSI, when it was realized that these spermatids could be harvested, and normal pregnancy rates achieved, in the ~60% of such patients who possessed this minuscule degree of spermatogenesis in otherwise completely deficient testicles.

There has been some excitement generated over the possibility of using 'round cells' derived from testicular tissue (or even from the ejaculate), which are presumably early spermatids, for ICSI in the absence of elongated spermatozoa. Infertility clinics around the world are now endeavouring to use this technique, which may have unfortunate implications.

The landmark study of Ogura and Yanagimachi (1993; Ogura *et al.*, 1993, 1994) demonstrated in mice that fertilization and occasional liveborn offspring could arise from the use of early round spermatids. However, these mice had normal spermatogenesis, resulting in the availability of many mature spermatozoa, which would give much higher fertilization and pregnancy rates than the round spermatids. This work was followed by a host of clinical efforts attempting to fertilize human eggs with ICSI using 'round cells' (Sofikitis *et al.*, 1994; Fishel *et al.*, 1995; Tesarik and Mendoza, 1996; Tesarik *et al.*, 1996).

The problems with this approach are: (i) in human spermatogenesis, it is widely known that 'maturation arrest' is a problem associated with meiosis, and not with sperm maturation. Wherever there are early round spermatids, there will also be elongated mature spermatids with a tail (Silber *et al.*, 1996; W.Schulze, personal communication, 1996); and (ii) clinics not aware of this reality are tempted to inject 'round cells' when they cannot retrieve spermatozoa. The truth is, that if those round cells were genuinely spermatids, then a better search would have revealed the presence of mature spermatozoa. On the other hand, it is extremely difficult, using Hoffman optics, to distinguish with certainty a round spermatid from a Sertoli cell nucleus with its prominent nucleolus, or even from some spermatocytes. Where there are truly no spermatozoa, there may be many 'round cells' either with Sertoli cell only, or with maturation arrest, that are not round spermatids.

The current ability of most men to father a child, regardless of the quality of the sperm count, even if there are apparently no mature spermatozoa at all, is dramatic. It appears that the results of ICSI are related neither to the source of the spermatozoa (whether ejaculated, testicular or epididymal), nor to the quality of the spermatozoa (morphology or motility). ICSI results are not influenced by whether the spermatozoon has been frozen or is fresh, whether it is retrieved with ease (as in the cases of normal spermatogenesis or with ejaculated spermatozoa), or whether the spermatozoon was extracted directly from the Sertoli cell after hours of painstaking searching of a testis sample (see Table III). With regard to the infertile or azoospermic male and ICSI, none of these factors has had any significant influence on fertilization, cleavage or pregnancy rate. In fact, the only significant factor in the success of ICSI appears to be the age of the female partner (Silber *et al.*, 1995c). Regardless of the source of the spermatozoa, their quality or the diagnosis in the male, the success rate appears to be determined only by the age of the wife (see Table IV).

Table III. Success of intracytoplasmic sperm injection (ICSI) with different sources of spermatozoa. From Nagy *et al.* (1995b)

Source of spermatozoa	No. of cycles	2 PN (%)	Transfer (%)	Clinical pregnancies (%)
Ejaculated	965	70	93	30
Fresh epididymal	43	56	93	30
Frozen epididymal	9	56	100	33
Testicular	17	48	77	39

Are the babies normal?: the genetics of ICSI

If the most important refinement of ICSI in 1994 and 1995 was the development of TESE–ICSI for cases of non-obstructive azoospermia, the major development in 1996 was the detailed follow-up study of ICSI babies and the information it provided about the genetics of infertility. In this volume, Liebaers and Bonduelle describe the extensive follow-up studies of ICSI babies who underwent chromosomal evaluation at amniocentesis or chorionic villus sampling (CVS), as well as a detailed 2 year paediatric follow-up. In the first

Table IV. Effect of age of wife upon pregnancy rate when the husband has obstructive azoospermia

Age of wife (years)	No. of cycles	No. of eggs at MII	2 PN (%)	Normal cleaved embryos	Ongoing and delivered pregnancies per cycle
<30	48 (26%)	907	382 (42%)	292 (76%)	22 (46%)
30–36	87 (48%)	1111	610 (55%)	413 (68%)	30 (34%)
37–39	22 (12%)	195	104 (53%)	84 (81%)	3 (14%)
40+	25 (14%)	281	147 (52%)	101 (69%)	1 (4%)
Totals	182 (100%)	2494	1243 (54%)	890 (70%)	56 (31%)

MII = metaphase II.

Table V. Malformation rates at birth in the general population

Reference	Malformation Major	Minor	Sample size
Marden *et al.* (1964)	2.1%	14.7%	4 412
Myrianthopoulos *et al.* (1974)	7.1%	7.3%	53 257
Mehes (1983)	2.2%	17.2%	4 589
Leppig *et al.* (1987)	3.8%	40.7%	4 305

877 consecutive ICSI babies born in the Brussels Dutch-Speaking Free University programme, thus far there has been no greater incidence of major or minor congenital abnormalities than is seen in routine screenings of normal large populations. The chromsomal studies of ICSI pregnancies are similarly reassuring. Firstly, of the 877 ICSI babies who underwent detailed paediatric follow-up by Bonduelle *et al.*, 448 were male and 429 were female, indicating no significant difference in sex ratio. The overall incidence of major congenital malformations in these 877 children was 2.6%, which is no different from the incidence of similar major malformations in many studies involving very large samples of normal populations (from 2.1 to 3.6%; see Tables V, VI and VII). In 1995, the ICSI task force also reported 18 major malformations in 763 children, which corresponds to the report of Bonduelle *et al.* of 2.6% [Office of Population Consensus and Surveys, 1987–1988; Congenital Malformation Statistics, 1979–1985, London: HMSO (OPC Series MB3); and National Perinatal Statistics Unit and the Fertility Society of Australia, 1992; IVF and GIFT Pregnancies, Australia and New Zealand, 1990; Sydney National Perinatal Statistics Unit (NPSU); and New York State Department of Health, 1990, Congenital Malformations Registry Annual Report; Statistical Summary of Children Born in 1986 and Diagnosed through 1988.

Table VI. Malformation rates in assisted reproduction surveys

Country and reference	Rate (%)
Great Britain	
Beral and Doyle (1990) (MRC Working Party on children conceived by IVF)	2.2
Rizk *et al.* (1991) (single centre)	2.5
Australia and New Zealand	
Assisted conception 1995	2.5
France	
Rufat *et al.* (1994) (national survey)	2.9
Israel	
Friedler *et al.* (1992) (national survey)	2.2
USA	
Medical Research International Society for Assisted Reproductive Technology (SART), 1995 (national survey)	2.3
Schattman *et al.* (1995) (single centre)	3.6

Table VII. Malformation rates in children born after intracytoplasmic sperm injection (ICSI)

Reference	No. of major malformations/ no. of children born (%)
Bonduelle *et al.* (1995)	23/848 (2.7)
Govaerts *et al.* (1995)	3/76 (3.9)
ICSI Task Force (1995)	18/763 (2.3)

Table VIII. Abnormal results obtained from 486 prenatal tests of intracytoplasmic sperm injection (ICSI) pregnancies. From Bonduelle *et al.* (1995)

Result	Method	Outcome	Maternal age (years)
Sex chromosomal (1.0%)			
47,XXX	CVS	singleton born	32
46,XX/47,XXX	CVS	singleton intrauterine death	44
47,XXY	CVS	twin born	28
47,XYY	amniocentesis	singleton born	25
47,XXY	amniocentesis	singleton interrupted	28
Autosomal (0.2%)			
47,XY,t21	CVS	singleton interrupted	41

CVS = chorionic villus sampling.

Table IX. Inherited balanced chromosomal aberrations in intracytoplasmic sperm injection (ICSI) pregnancies (n = 6/486 = 1.2%). From Bonduelle *et al.* (1995)

Karyotype	Type of pregnancy and mode of transmission
46,XY, inv (1)(p22p23.2)	singleton, paternally transmitted
46,XY, inv (5)(p13q13)	singleton, paternally transmitted
47,XX, + inv dup (15p)×2	twins, paternally transmitted
45,XY,t(13;14)	singleton, paternally transmitted
45,XX,t(14;15)	singleton, paternally transmitted

[a]Bonduelle *et al.* (1995).

Table X. Summary of chromosomal anomalies after intracytoplasmic sperm injection (ICSI). From Bonduelle *et al.* (1995)

Anomaly	Rate (%)
Abnormal	
Sex chromosomal	5/486 (1.0)
Autosomal	1/486 (0.2)
Balanced anomalies inherited from father	6/486 (1.2)

The results of chromosomal studies from amniocentesis and CVS of the first 486 fetuses undergoing prenatal testing, although reassuring, deserve special consideration (see Tables VIII, IX and X). Six of these 486 prenatal chromosomal evaluations (1.2%) showed de-novo abnormalities not transmitted directly from the father. Five of these abnormalities were sex chromosomal in nature, and only one (0.2%) was an autosomal abnormality. This latter abnormality was a Down'syndrome (47XY,T-21) picked up on CVS in a 41 year old woman, and this pregnancy was terminated. A 0.2% incidence of trisomy 21 in a 41 year old woman is to be expected in any population of women of that age and certainly is in no way attributable to the ICSI procedure or to the infertility of the husband.

However, the five de-novo sex chromosomal abnormalities (1.0%) represent an incidence greater than the 0.2% incidence expected in a normal population of newborns. Of these five anomalies, one was 47,XXX, one 46,XX/47,XXX mosaic, two 47,XXY Klinefelter's, and one 47,XYY. Although this incidence of sex chromosomal aneuploidies certainly exceeds the expected population norm seen in newborns, most parents did not express serious concern about this and elected to interrupt the pregnancy in only one case, a Klinefelter's. These children with sex chromosomal abnormalities appear to be normal in every other way.

The incidence of autosomal chromosomal abnormalities inherited from the parents was 1.0%. All were paternally transmitted chromosomal aberrations seen in the father prior to ICSI during the initial counselling. The transmission of these abnormalities from the father to the child was not of serious concern to most of the parents. These inherited structural chromosomal anomalies included three inversions and two balanced translocations. Thus, the results of detailed follow-up of ICSI pregnancies and delivered babies are very reassuring, but suggest that there may be a very slightly higher risk (1%) than normal of sex chromosomal abnormalities in these children. Furthermore, attention must be given to the possibility of

Table XI. Autosome abnormalities observed in infertile men (including azoospermic and oligozoospermic males). From Van Assche *et al.* (1996)

	Number	Robertsonian translocation	Reciprocal translocation	Inversion	Extra marker	Total
Total	7 876	45 (0.6)	36 (0.5)	8 (0.1)	8 (0.1)	104 (1.3)
Newborn studies	94 465	76 (0.08)	98 (0.10)	23 (0.02)	35 (0.04)	363 (0.38)

Table XII. Chromosome abnormalities observed in seven series of infertile men compared with normal newborn population. From Van Assche *et al.* (1996)

References	Number	Sex chromosome	Autosomes	Total
Koulischer and Schoysman (1974)	1000	27 (2.7)	6 (0.6)	33 (3.3)
Chandley (1979)	2372	33 (1.4)	18 (0.7)	51 (2.1)
Zuffardi and Tiepolo (1982)	2542	175 (6.9)	40 (1.6)	215 (8.6)
Abramsson *et al.* (1982)	342	6 (1.8)	4 (1.2)	10 (2.9)
de Gardelle *et al.* (1983)	318	13 (4.1)	7 (2.2)	20 (6.3)
Matsuda *et al.* (1989)	295	0 (0)	5 (1.7)	5 (1.7)
Yoshida *et al.* (1995)	1007	41 (4.1)	24 (2.4)	65 (6.5)
Total in infertile men	7876	295 (3.8)	104 (1.3)	399 (5.1)
Total in newborn infants	94465	131 (0.14)	232 (0.25)	366 (0.38)

the occasional balanced translocation in the father giving rise to a rare unbalanced translocation in the fetus.

The genetics of infertile men about to undergo ICSI

Genetics of oligozoospermia and germinal failure

The increased incidence of paternally transmitted translocations and inversions in infertile men has been deduced from detailed chromosomal evaluations performed on 694 patients and their wives prior to undergoing the ICSI procedure, as well as from a detailed review of the literature of chromosomal evaluations in infertile men (see Tables XI and XII). From 1975 until the present time, reports have been published on 7876 infertile men who have undergone karyotyping. Of these, 3.8% were found to have sex chromosomal abnormalities and 1.3% were found to have autosomal chromosomal abnormalities, giving a total of 5.1% chromosomal abnormalities in this large population. This compares to the incidence in newborn infants of sex chromosomal abnormalities of 0.14%, autosomal chromosomal abnormalities of 0.25%, and of total chromosomal abnormalities in the newborn population of 0.38% (Koulischer and Schoysman, 1974; Chandley, 1979; Abramsson *et al.*, 1982; Zuffardi and Tiepolo, 1982; Gardelle *et al.*, 1983; Matsuda *et al.*, 1989; Yoshida *et al.*, 1995). The incidence of sex chromosomal abnormalities in newborn infants (0.14%) is therefore much less than that in azoospermic males. The average 3.8% incidence of sex chromosomal abnormalities obtained from all these studies was different from that shown in the study of Matsuda *et al.* (1989), which found no sex chromosomal abnormalities in azoospermic men but a 1.7% incidence of autosomal abnormalities. The great majority of sex chromosomal abnormalities in azoospermic men appear to be XXY Klinefelter's syndrome, with other sex chromosomal abnormalities occurring in only 0.6% of azoospermic men.

Of the total of 1.3% of infertile men in these published reports who had autosomal abnormalities, there was an approximately equal number of Robertsonian translocations and reciprocal translocations, with a smaller number of inversions and extra markers. The incidence of autosomal abnormalities in newborn infants (0.25%) is one-

fifth of that found in infertile men. In azoospermic males, 1.1% have autosomal abnormalities. In the Brussels series of severe oligozoospermic, asthenozoospermic and teratozoospermic men, as well as men with oligoasthenoteratozoospermia, only 0.3% had sex chromosomal abnormalities, while none of the men who failed to exhibit any of the three defects had sex chromosomal abnormalities. On average, 2% of men with severe oligozoospermia or oligoasthenoteratozoospermia exhibited chromosomal defects, a rate 5–6 times greater than that of a normal population. These chromosomal defects result in a higher rate of miscarriage and the transmission of paternal chromosomal defects to the offspring. Therefore, in a very small percentage of infertile men (2%), chromosomal abnormalities create meiotic difficulties that appear to interfere with spermatogenesis. However, there are many more subtle genetic defects that appear to be responsible for male factor infertility that will not show up in routine chromosomal analysis.

In a study initiated by David Page and myself, 89 men with non-obstructive azoospermia caused either by maturation arrest, Sertoli cell-only, or a combination of these two histological defects, underwent detailed sequence-tagged sites (STS) mapping of the Y chromosome. This demonstrated microdeletions in 13% of patients, located at the distal portion of the euchromatic region of the Y, which is positioned approximately in the middle of the long arm of the Y. These microdeletions can be detected with mapping signposts, which currently have a sensitivity of only 20 000 base pairs. Thus, it is very possible that many more, much smaller, mutations in the Y chromosome, perhaps in the region termed *DAZ*, may be responsible for varying degrees of azoospermia and oligozoospermia (Reijo *et al.*, 1995; Silber, 1995; Silber *et al.*, 1995a,c). This region of the human genome is particularly difficult to sequence accurately because of the presence of so many confusing 'Y-specific repeats.' These repeats also explain why this region is so very prone to spontaneous mutations and perhaps also why male infertility is very common in the human.

It is easy to interpret incorrectly as deletions what are in truth polymorphisms, because most of the Y chromosome does not undergo recombination and is truly a degenerate chromosome. However, our study controlled for that possibility by finding no such deletions in the fathers or brothers of these azoospermic men, who incidentally were fertile. The questions can be raised, why do some of these men have occasional spermatozoa recoverable from the testes, and also what causes azoospermia in the other 87% of azoospermic men with Sertoli cell only or maturation arrest? One new avenue to explore is the finding that the Y deleted *DAZ* gene also occurs on autosome 3 in humans, thus introducing issues of recombination and dominance (Saxena *et al.*, 1996).

Even Klinefelter's syndrome patients (XXY), who were originally thought not to be able to father children, often have a minute amount of sperm production that can be discovered in the testis. These patients can undergo the TESE–ICSI procedure and produce normal embryos that presumably lead to a pregnancy. The question arises as to whether the spermatozoa from these Klinefelter's patients, which are presumably like the spermatozoa from other severely infertile men, yielding offspring with a higher incidence of sex chromosomal abnormalities, may be a heterogeneous population of some that are disomic for XX, some that are disomic for XY, as well as some that are normal haploid Y or normal haploid X. If this were the case, it would indicate that an offspring would have a 50% chance of also having a sex chromosomal abnormality. However, if the opposite theory is true, that it is only the mosaically normal areas of the seminiferous tubules that are producing spermatozoa, then presumably the ratio of X and Y spermatozoa in the testes of these men would not differ from normal, and there would be no increased risk of sex chromosomal abnormalities in the children. To test this concept, routine preimplantation genetic diagnosis has been performed on all Klinefelter's patients undergoing TESE–ICSI (Staessen *et al.*, 1996). Thus far, the replaceable embryos have not had sex chromosomal abnormalities, with the exception of one which was a mosaic of XXY and XY. Therefore, this matter still remains under question.

Thus, because the ICSI procedure allows us to produce fertilized eggs using spermatozoa from

almost any man, no matter how apparently sterile, we have been better able to study and understand the genetic causes of male infertility, and the possible transference of male infertility to the male offspring generated by the ICSI procedure. Perhaps this will lead to a greater understanding in the future, and to improved treatment of these genetic causes of male infertility.

Cystic fibrosis

The genetics of cystic fibrosis and congenital male obstructive infertility have been studied in great detail as a result of the introduction of ICSI (Silber *et al.*, 1991; Anguiano *et al.*, 1992; Chillon *et al.*, 1995). Previously, there was no evidence to suggest that congenital absence of the vas might be a genetic condition transmitted via the cystic fibrosis gene. The only clue was the clinical observation that all men with cystic fibrosis also have congenital absence of the vas deferens. However, the majority of men visiting fertility clinics because of azoospermia caused by congenital absence of the vas deferens had normal sweat chloride tests and no clinical signs of cystic fibrosis. Yet, genetic studies showed that 70% of these men had common cystic fibrosis mutations on one allele, and 10% had common cystic fibrosis mutations on both alleles. In those cases where both alleles were affected, one of the mutations was always extremely mild. Today, men with frank cystic fibrosis, with both alleles having strong mutations, are also presenting at fertility clinics to attempt to achieve pregnancy with MESA–ICSI.

The big mystery has been why 30% of cases show no cystic fibrosis mutations, while 60% have only one allele affected. Studies performed by the Cystic Fibrosis Consortium in Europe in which the entire coding region of the cystic fibrosis genes was scanned revealed absolutely no mutations in these men, meaning that the problem was not one of a hidden, undiscovered mutation in any of the exons or coding regions. However, a splicing error in intron 8, called the T_5 allele, was found to be on the opposite allele of a patient who was heterozygous for cystic fibrosis, but in both alleles of those who showed no mutations. This resulted in a defective production of CFTR protein that was adequate to prevent cystic fibrosis but inadequate to prevent congenital absence of the vas deferens.

Thus, use of ICSI for treatment of the most severe cases of male factor infertility is leading to major molecular genetic discoveries that would never have been anticipated in the era of classical andrology.

References

Abramsson, L., Beckman, G., Duchek, M. and Nordenson, I. (1982) Chromosomal aberrations in male infertility. *J. Urol.*, **128,** 52–53.

Anguiano, A., Oates, R.D., Amos, J.A. *et al.* (1992) Congenital bilateral absence of the vas deferens: a primarily genital form of cystic fibrosis. *J. Am. Med. Assoc.*, **267,** 1794–1797.

Australia and New Zealand (1995) Assisted conception. *Aust. N.Z. J. Obstet. Gynaecol.*, **35,** 27–31.

Beral, V. and Doyle, P. (1990) Report of the MRC Working Party on Children Conceived by In Vitro Fertilization. Births in Great Britain resulting from assisted conception, 1978–87. *Br. Med. J.*, **300,** 1229–1233.

Bonduelle, M., Legein, J., Buysse, A. *et al.* (1995) Prospective follow-up study of 423 children born after intracytoplasmic sperm injection. *Hum. Reprod.*, **11,** 1558–1564.

Chandley, A.C. (1979) The chromosomal basis of human infertility. *Br. Med. Bull.*, **35,** 181–186.

Chillon, M., Casals, T., Mercier, B. *et al.* (1995) Mutations in the cystic fibrosis gene in congenital absence of the vas deferens. *N. Engl. J. Med.*, **332,** 1475–1480.

de Gardelle, G.R., Jaffray, J.Y., Geneix, A. and Malet, P. (1983) Les anomalies due caryotype dans les sterilites hypofertilites masculines. *Pathologica*, **75,** 687–691.

Devroey, P., Silber, S., Nagy, Z. *et al.* (1994) Ongoing pregnancies and birth after intracytoplasmic sperm injection (ICSI) with frozen–thawed epididymal spermatozoa. *Hum. Reprod.*, **10,** 903–906.

Devroey, P., Liu, J., Nagy, Z. *et al.* (1995) Pregnancies after testicular extraction (TESE) and intracytoplasmic sperm injection (ICSI) in non-obstructive azoospermia. *Hum. Reprod.*, **10,** 1457–1460.

Dumur, V., Gervais, R., Rigot, M. *et al.* (1990) Abnormal distribution of CF ΔF508 allele in azoospermic men with congenital aplasia of epididymis and vas deferens. *Lancet*, **336,** 512–517.

Fishel, S., Green, S., Bishop, M. *et al.* (1995) Pregnancy after intracytoplasmic injection of spermatid. *Lancet*, **345,** 1641–1642.

Friedler, S., Mashiach, S. and Laufer, N. (1992) Births in Israel resulting from in-vitro fertilization/embryo transfer, 1982–1989. National Registry of the Israeli Association for Fertility Research. *Hum. Reprod.*, **7,** 1159–1163.

Govaerts, I., Englert, Y., Vamos, E. and Rodesch, F. (1995) Sex chromosome abnormalities after intracytoplasmic sperm injection (letter; comment). *Lancet*, **21,** 1095–1096.

Handyside, A.H. (1993) Diagnosis of inherited disease before implantation. *Reprod. Med. Rev.*, **2,** 51–61.

ESHRE ICSI Task Force (1995) ESHRE Central Office, Van Akenstraat 41, B-1850 Grimbergen, Belgium.

Koulischer, L. and Schoysman, R. (1974) Chromosomes and human infertility. Mitotic and meiotic chromosome studies in 202 consecutive male patients. *Clin. Genet.*, **5,** 116–126.

Leppig, K.A., Werler, M.M., Cann, C.I. *et al.* (1987) Predictive value of minor anomalies, association with major anomalies. *J. Pediatr.*, **110,** 531–537.

Liu, J., Nagy, Z., Joris, H. *et al.* (1994a) Intracytoplasmic sperm injection does not require a special treatment of the spermatozoa. *Hum. Reprod.*, **9,** 1127–1130.

Liu, J., Lissens, W., Silber, S.J. *et al.* (1994b) Birth after preimplantation diagnosis of the cystic fibrosis ΔF508 mutation by polymerase chain reaction in human embryos resulting from intracytoplasmic sperm injection with epididymal sperm. *J. Am. Med. Assoc.*, **23,** 1858–1860.

Liu, J., Nagy, Z., Joris, H. *et al.* (1995) Analysis of 76 total fertilization failure cycles out of 2732 intracytoplasmic sperm injections cycles. *Hum. Reprod.*, **10,** 2630–2636.

Marden, P.M., Smith, D.W. and McDonald, M.J. (1964) Congenital anomalies in the newborn infant including minor variations. A study of 4412 babies by surface examination for anomalies and buccal smear for sex chromatin. *J. Pedriatr.*, **64,** 357–371.

Matsuda, T., Nonomura, M., Okada, K. *et al.* (1989) Cytogenetic survey of subfertile males in Japan. *Urol. Int.*, **44,** 194–197.

Medical Research International Society for Assisted Reproductive Technology (SART) and The American Fertility Society (1995) Assisted reproductive technology in the United States and Canada: 193 results generated from the American Society for Reproductive Medicine/Society for Assisted Reproductive Technology Registry. *Fertil. Steril.*, **64,** 13–21.

Mehes, K. (1983) Association of supernumerary nipples with other anomalies (letter). *J. Pediatr.*, **102**(a), 161.

Myrianthopoulos, N.C. and Chung, C.S. (1974) Congenital malformations in singletons: epidemiologic survey. Report from the Collaborative Perinatal Project. *Birth Defects*, **10,** 1–58.

Nagy, Z., Liu, J., Joris, H. *et al.* (1995a) The result of intracytoplasmic sperm injection is not related to any of the three basic sperm parameters. *Hum. Reprod.*, **10,** 1123–1129.

Nagy, Z., Liu, J., Janssenwillen, C. *et al.* (1995b) Comparison of fertilization, embryo development and pregnancy rates after intracytoplasmic sperm injection using ejaculated, fresh, and frozen–thawed epididymal and testicular sperm. *Fertil. Steril.*, **63,** 808–815.

Ogura, A. and Yanagimachi, R. (1993) Round spermatid nuclei injected into hamster oocytes form pronuclei and participate in syngamy. *Biol. Reprod.*, **48,** 219–225.

Ogura, A., Yanagimachi, R. and Usui, N. (1993) Behavior of hamster and mouse round spermatid nuclei incorporated into mature oocytes by electrofusion. *Zygote*, **1,** 1–8.

Ogura, A., Matsuda, J. and Yanagimachi, R. (1994) Birth of normal young after electrofusion of mouse oocytes with round spermatids. *Proc. Natl. Acad. Sci. USA*, **91,** 7460–7462.

Palermo, G., Joris, H., Devroey, P. and Van Steirteghem, A. (1992) Pregnancies after intracytoplasmic injection of single spermatozoa into an oocyte. *Lancet*, **340,** 17–18.

Reijo, R., Lee, T.-Y., Salo, P. *et al.* (1995) Diverse spermatogenic defects in humans caused by Y chromosome deletions encompassing a novel RNA-binding protein. *Nature Genet.*, **10,** 383–393.

Rizk, B., Doyle, P., Tan, S.L. *et al.* (1991) Prenatal outcome and congenital malformations in in-vitro fertilization babies from the Bourn–Hallam group. *Hum. Reprod.*, **6,** 1259–1264.

Rufat, P., Oliviennes, F. *et al.* (1994) Task force report on the outcome of pregnancies and children conceived by in vitro fertilization (France: 1987 to 1989). *Fertil. Steril.*, **61,** 324–330.

Saxena, R., Brown, L.G., Hawkins, T. *et al.* (1996) The *DAZ* gene cluster on the human Y chromosome arose from an autosomal gene that was transposed, repeatedly amplified and pruned. *Nature Genet.*, **14,** 292–299.

Schattman, G., Rosenwaks, Z., Berkely, A. *et al.* (1995) Congenital malformations in children born utilizing the assisted reproductive technologies. In *Serono International Symposium on Genetics of Gametes and Embryos*, June 2–5, New York, p. 36.

Schoysman, R., Vanderzwalmen, P., Nijs, M. *et al.* (1993) Pregnancy after fertilisation with human testicular spermatozoa. *Lancet*, **342,** 1237.

Silber, S.J. (1989a) Results of microsurgical vasoepididymostomy: role of epididymis in sperm maturation. *Hum. Reprod.*, **4,** 298–303.

Silber, S.J. (1989b) Pregnancy after vasovasostomy for vasectomy reversal: a study of factors affecting long-term return of fertility in 282 patients followed for 10 years. *Hum. Reprod.*, **4,** 318–322.

Silber, S.J. (1995) What forms of male infertility are there left to cure? *Hum. Reprod.*, **10,** 503–504.

Silber, S.J. and Rodriguez-Rigau, L.J. (1981) Quantitative analysis of testicle biopsy: determination of partial obstruction and prediction of sperm count after surgery for obstruction. *Fertil. Steril.*, **36,** 480–485.

Silber, S.J., Ord, T., Balmaceda, J. *et al.* (1991) Cystic fibrosis and congenital absence of the vas deferens. *N. Engl. J. Med.*, **323,** 1788–1792.

Silber, S.J., Nagy, Z.P., Liu, J. *et al.* (1994) Conventional in-vitro fertilization versus intracytoplasmic sperm injection for patients requiring microsurgical sperm aspiration. *Hum. Reprod.*, **9,** 1705–1709.

Silber, S.J., Van Steirteghem, A.C. and Devroey, P. (1995a) Sertoli cell only revisited. *Hum. Reprod.*, **10,** 1031–1032.

Silber, S.J., Devroey, P., Tournaye, H. and Van Steirteghem, A.C. (1995b) Fertilizing capacity of epididymal and testicular sperm using intra-cytoplasmic sperm injection (ICSI). *Reprod. Fertil. Dev.*, **7,** 281–293.

Silber, S.J., Nagy, Z., Liu, J. *et al.* (1995c) The use of epididymal and testicular spermatozoa for intracytoplasmic sperm injection: the genetic implications for male infertility. *Hum. Reprod.*, **10,** 2031–2043.

Silber, S.J., Van Steirteghem, A.C., Liu, J. *et al.* (1995d) High fertilization and pregnancy rate after intracytoplasmic sperm injection with sperm obtained from testicle biopsy. *Hum. Reprod.*, **10,** 148–152.

Silber, S.J., Van Steirteghem, A.C., Nagy, Z. *et al.* (1996) Normal pregnancies resulting from testicular sperm extraction and intracytoplasmic sperm injection for azoospermia due to maturation arrest. *Fertil. Steril.*, **55,** 110–117.

Sofikitis, N.V., Miyagawa, I., Agapitos, E. *et al.* (1994) Reproductive capacity of the nucleus of the male gamete after completion of meiosis. *J. Assist. Reprod. Genet.*, **11,** 335–341.

Steinberger, E. and Tjioe, D.Y. (1968) A method for quantitative analysis of human seminiferous epithelium. *Fertil. Steril.*, **19,** 960–970.

Tesarik, J. and Mendoza, C. (1996) Spermatid injection into human oocytes. I. Laboratory techniques and special features of zygote development. *Hum. Reprod.*, **11,** 772–779.

Tesarik, J., Rolet, F., Brami, C. *et al.* (1996) Spermatid injection into human oocytes. II. Clinical application in the treatment of infertility due to non-obstructive azoospermia. *Hum. Reprod.*, **11,** 780–783.

Tournaye, H., Devroey, P., Liu, J. *et al.* (1994) Microsurgical epididymal sperm aspiration and intracytoplasmic sperm injection: a new effective approach to infertility as a result of congenital bilateral absence of the vas deferens. *Fertil. Steril.*, **61,** 1045–1051.

Van Assche, E., Bonduelle, M., Tournaye, H. *et al.* (1996) Cytogenetics of infertile men. *Hum. Reprod.*, **11** (Suppl. 4), 1–26.

Van Steirteghem, A.C., Nagy, Z., Joris, H. *et al.* (1993) High fertilization and implantation rates after intracytoplasmic sperm injection. *Hum. Reprod.*, **8,** 1061–1066.

Yoshida, A., Kamayama, T., Nagao, K. *et al.* (1995) A cytogenetic survey of 1007 infertile males. *Contracept. Fertil. Sex.*, **23,** 103a.

Zuckerman, Z., Rodriguez-Rigau, L.J., Weiss, D.B. *et al.* (1978) Quantitative analysis of the seminiferous epithelium in human testicle biopsies and the relation of spermatogenesis to sperm density. *Fertil. Steril.*, **30,** 448–455.

Zuffardi, O. and Tiepolo, L. (1982) Frequencies and types of chromosome abnormalities associated with human male infertility. In Crosignani, P.G. and Rubin, B.L. (eds), *Genetic Control of Gamete Production and Function*. Serono Clinical Colloquia on Reproduction III. Academic Press and Grune and Stratton, London, pp. 261–273.