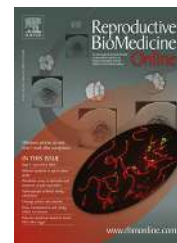



www.sciencedirect.com
www.rbmonline.com



ARTICLE

Fresh and cryopreserved ovary transplantation and resting follicle recruitment




Sherman Silber ^{a,*}, Jorge Pineda ^a, Kathleen Lenahan ^a, Michael DeRosa ^a, Jeffrey Melnick ^b

^a Infertility Center of St Louis, St Luke's Hospital, 224 South Woods Mill Road, Saint Louis, MO 63017, USA; ^b Department of Pathology, St Luke's Hospital, 232 South Woods Mill Road, St Louis, MO 63017, USA

* Corresponding author. E-mail address: silber@infertile.com (S Silber).



Dr Sherman Silber is a pioneer in microsurgery and infertility. He performed the earliest microsurgical vasectomy reversals, the first testicle transplant in the 1970s, and, more recently, the first ovary transplant. He was the earliest developer of the TESE and MESA techniques for retrieving testicular and epididymal sperm in azoospermic men. He headed the clinical portion of the MIT team that first mapped and sequenced the Y chromosome in infertile men and discovered the DAZ gene for male fertility. He has authored textbooks for clinicians and patients, and more than 250 scientific papers on human infertility and reproduction.

Abstract Ovary cryopreservation and transplantation has garnered increasing interest as a possible method to preserve fertility for cancer patients and to study ovarian resting follicle recruitment. Eleven consecutive women underwent fresh donor ovary transplantation, and 11 underwent cryopreserved ovary auto-transplantation in the same centre, with the same surgeon. Of the 11 fresh transplant recipients, who were all young but menopausal, nine women had normal ovarian cortex transplanted from an identical twin sister, and two had a fresh allograft from a non-identical sister. In the second group, 11 women with cancer had ovarian tissue cryopreserved before bone marrow transplant, and then after years of therapeutically induced menopause, underwent cryopreserved ovarian cortex autotransplantation. Recovery of ovarian function and follicle recruitment was assessed in all 22 recipients, and the potential for pregnancy was further investigated in 19 (11 fresh and 8 cryopreserved) with over 1-year follow-up. In all recipients, normal FSH levels and menstruation returned by about 150 days, and anti-Müllerian hormone reached much greater than normal concentrations by about 170 days. Anti-Müllerian hormone levels then fell below normal by about 240 days and remained at that lower level. Seventeen babies have been born to these 11 fresh and eight cryopreserved ovary transplant recipients. 

© 2015 Reproductive Healthcare Ltd. Published by Elsevier Ltd. All rights reserved.

KEYWORDS: fertility, follicle recruitment, ovarian cryopreservation, transplant

Introduction

Successful fresh and cryopreserved ovarian cortex transplants in humans were first published in 2004 and 2005, as case reports, and many other case reports have subsequently followed (Andersen et al., 2008; Demeestere et al., 2003, 2010; Dittrich et al., 2012; Donnez et al., 2004, 2011, 2013; Kagawa et al., 2009; Meirow et al., 2005; Poirot et al., 2012; Revel et al., 2011; Revelli et al., 2013; Sanchez et al., 2007; Silber et al., 2012; Silber and Gosden, 2007; Silber et al., 2005, 2008a, 2008b; Stern et al., 2013; Stoop et al., 2014). The first human applications were preceded by a long history of animal experimentation. As far back as 1954, Deanesly showed in rats and, in 1960, Parrott showed in mice, that ovarian tissue could be successfully frozen and autografted resulting in live births (Deanesly, 1954; Parrott, 1960). Interest in human applications began after Gosden's report of successful pregnancies in sheep in 1994 (Gosden et al., 1994). One of the most interesting case reports in humans involved rejuvenating menopausal ovarian cortex with cryopreserved autotransplantation (Kawamura et al., 2013). Interest in cryopreserved ovarian cortical transplantation is rapidly growing, although only one report to date has clearly stated its success rate (Donnez et al., 2013). No systematic report has been published from one centre comparing fresh donor transplants and cryopreserved ovary autografts, and little has been gleaned from studies of these procedures on analysis of ovarian function and resting follicle recruitment (Oktay et al., 2001).

The primary impetus for this procedure has been to cryopreserve ovarian tissue before sterilizing cancer treatment, with the objective of transplanting the tissue back after cancer has been cured, thus allowing patients to preserve their fertility. It is also possible that grafts taken from young women with cancer could be used to delay their menopause in the future (Andersen et al., 2012; Aydin et al., 2010; Faddy et al., 1992; Gosden et al., 1989; Kaaijk et al., 1999; Kim, 2003; Koskas et al., 2011; Lass et al., 1997; Meredith et al., 1992; Saiduddin et al., 1970; Stoop et al., 2014; Yasui et al., 2012; Zhai et al., 2012). The possibility of preserving fertility and even hormonal function against the natural decline caused by ageing has also been speculated, but is considered of less importance (Andersen et al., 2012; Cobo et al., 2008; Homburg et al., 2009; Nagy et al., 2009; Stoop et al., 2014).

Most published research in this field consists of case reports of cryopreserved transplants only. We conducted a worldwide survey of 37 babies born from cryopreserved transplants, but still could not establish a clear success rate (Stoop et al., 2014). Here, we report a single series of both fresh and cryopreserved transplants from one centre, carried out with the same technique and assessed uniformly over follow-up, with the aim of improving our understanding of resting follicle recruitment and demonstrating the clinical robustness of the procedure.

Materials and methods

Patients

Between 2004 and 2013, a total of 22 patients underwent either fresh or cryopreserved ovary transplantation to restore

fertility and hormonal function, and their outcomes and the control of primordial follicle recruitment in the human ovary were investigated. All cases of ovary preservation and transplantation were approved by the St Luke's Internatioanl Review Board and the St Luke's Ethics Committee (letters of approval dating back to 1997). All 22 patients were followed long enough (for the duration of the functional lifespan of the ovarian tissue) to evaluate resting follicle recruitment and menstrual cycle dynamics, and 19 (11 fresh and eight cryopreserved transplant recipients) also had a sufficiently long follow-up time (>1 year) to evaluate pregnancy potential. In all cases, fresh or cryopreserved, an entire ovary was removed, and in cryopreserved cases involving cancer, all pieces of cortex were cryopreserved. In fresh cases, only the pieces not used in the fresh transplant were cryopreserved.

Eleven patients (nine identical twins and two allograft recipients) underwent fresh ovarian cortex transplant from a fertile donor to a young but menopausal woman. In the two cases of fresh ovarian tissue allografting, a non-identical donor sister had previously donated bone marrow to the sister with cancer after sterilizing bone marrow transplant. An additional 11 patients more recently underwent a cryopreserved autotransplant, i.e. thawing and warming of their own prior cryopreserved ovarian cortex to restore fertility that was lost from cancer or autoimmune treatment many years earlier. In all cases, detailed histology of the recipient ovarian cortex before transplantation confirmed complete absence of any primordial or other follicles.

The technique of ovarian cortical transplantation used in this study is not exactly the same as others have reported (Donnez et al., 2004; Meirow et al., 2005), but it has been previously described in detail (Silber, 2013; Silber and Gosden, 2007; Silber et al., 2005, 2008a, 2008b). Except for one case conducted with microvascular anastomosis, all were ovarian cortical grafts onto denuded medulla with a classical skin grafting-type technique, as was originally reported by our group (Silber et al., 2005). For ovarian tissue cryopreservation, between 1997 and 2008, a classic slow freeze method was used (Gosden et al., 1994; Kagawa et al., 2009; Newton et al., 1996; Silber et al., 2005). Since 2008, only vitrification has been used (Kagawa et al., 2009; Keros et al., 2009; Silber et al., 2010).

Evaluation of resting follicle recruitment and menstrual ovulatory dynamics

All 22 transplant recipients had monthly follow-up of hormonal cycles and ovulation. Return of ovarian function was determined by monthly measurement of FSH, LH, oestradiol, anti-Müllerian hormone (AMH), and menstrual cycling. Once menstrual cycling returned, all hormone measurements were carried out on day 3 of the cycle. Unfortunately AMH was not measured in the first 13 cases. All patients were allowed to conceive spontaneously, and treatment intervention such as IVF was only resorted to in two cases, where fallopian tubes were absent or adherent.

Results

Of the nine menopausal women who underwent fresh transplantation of ovarian cortex from their identical twin donor

sister, 11 healthy babies (six boys and five girls including one pair of twins) were born from 14 pregnancies (four spontaneous abortions) (Table 1). The two allograft cases had complete return of ovulatory function for long periods. One individual has still-functioning tissue, whereas the other one conceived but spontaneously aborted. In this case, the patient underwent a bone marrow transplant almost 30 years ago as a 4-year-old child (one of the first paediatric bone marrow transplants ever performed) and received much higher radiation doses than are used in the modern era, possibly explaining her failure to become pregnant. All of the recipients had normal return of hormonal and menstrual ovarian function at about the same time after surgery (4.5 months) (Figure 1a).

In all fresh and cryopreserved transplant recipients, day 3 FSH decreased from the menopausal range to normal levels in about 150 days, and menstrual cycling resumed by roughly 130 days. Since all developing follicles were destroyed or excluded from the thin (1-mm) donor ovarian cortical graft, this period seems to represent the number of days required for resting primordial follicles to be recruited and develop to the ovulatory stage, at which point they finally become sensitive to cyclic FSH and LH (Figure 1).

The duration of function of fresh grafts was directly related to the original ovarian reserve of the donor. In all cases, only one-quarter to one-half of the donor ovary was transplanted, and most of the tissue cryopreserved for future use. All grafts functioned for more than 2 years, over one-half of them for

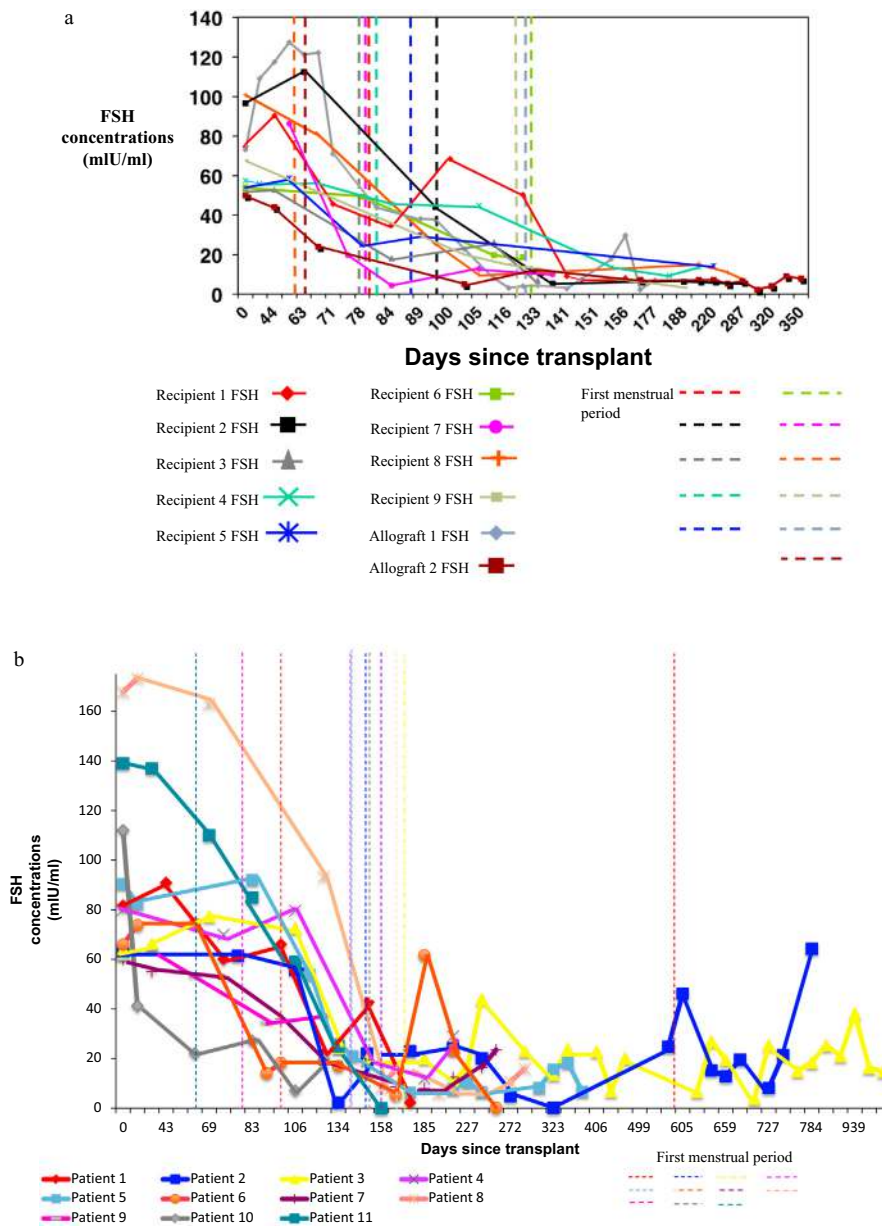


Figure 1 Levels of FSH after fresh or cryopreserved ovary graft. Time of first menstruation and the duration of time required for FSH levels to revert to normal levels, allowing for ovulation to occur, is represented for the 11 patients who received fresh ovary tissue transplants (a) and the 11 patients who received cryopreserved ovary tissue transplants (b).

Table 1 Pregnancy and duration of function of fresh donor ovarian grafts from an identical twin sister ($n = 9$) or non-identical sister allograft ($n = 2$).

Days of ovarian function	Date of transplant	Ovarian function end date	Spontaneous abortion	Baby Born	Girl	Boy
975	21 April 2004	22 December 2006	1	1	1	
3025	20 April 2005	1 August 2013		3	1	2
2285	7 June 2005	9 September 2011		2	1	1
1534	23 August 2005	4 November 2009	1	1		1
1107	20 September 2005	1 October 2008				
752	11 July 2006	1 August 2008		1	1	
2410+	16 August 2006	NA	2	2		2
1666	9 January 2007	1 February 2011		1	1	
618	21 April 2008	30 December 2009	1			
263 ^a	21 July 2010	10 April 2011				
1172+	11 February 2011	NA	1			
Total			6	11	5	6

NA = not applicable.

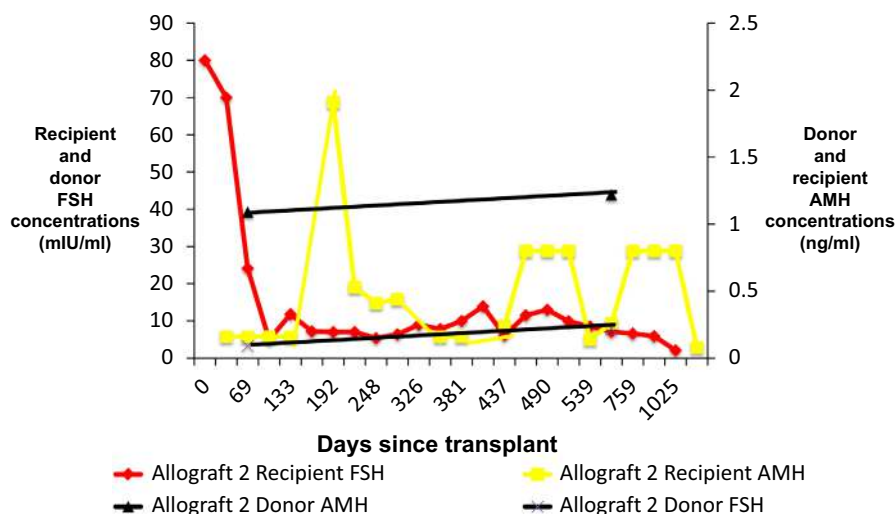
^aRejected when immunosuppression was discontinued.

over 6 years, and two of them already for over 8 years (Table 1). Thus if the donor's ovarian reserve is high, these grafts can last for a long time despite reduced AMH levels (Andersen et al., 2012; Silber et al., 2010).

The relationships among FSH levels, menstruation and AMH levels in donor and recipient in fresh transplants are indicative of resting follicle recruitment and ovarian reserve (La Marca et al., 2007). As recipient FSH levels returned to normal within 130–170 days, the low AMH level of recipients then began to rise in response to an increasing number of mature gonadotrophin-sensitive follicles (Figure 2). The AMH of recipients continued to rise to well above the normal baseline AMH level of the donor. In the fresh allograft recipient shown in Figure 2, although FSH decreased to normal levels by day 133 and normal menstrual cycling resumed, AMH levels rose far above normal (higher than the donor) shortly thereafter. Despite the transplanted graft continuing to function, AMH then returned to low levels. This analysis of both donor and recipient data after transfer is rare and

useful in its demonstration of no significant long-term change in donor AMH levels despite loss of an ovary. The rise of recipient AMH levels above donor AMH levels reflects over-recruitment of resting follicles in the recipient compared with the donor (Figure 2). Contrary to what might have been expected based on earlier studies (Baird et al., 1999), no evidence was found of significant loss of follicles from transplantation ischaemia, as each patient had FSH levels return to normal as AMH levels rose far above normal. Despite continued function of the transplanted graft, AMH then returns to low levels (Figures 3a–g). Preservation of follicles was supported by our observation of substantial follicle recruitment with many eggs produced in the two patients who underwent IVF during the window of high AMH levels. Quantitative studies have also supported this finding in bovines (Kagawa et al., 2009).

The auto-transplantation of cryopreserved ovary tissue yielded results almost identical to fresh transplantation (Figure 1b). This finding is consistent with the observed

**Figure 2** Levels of FSH and anti-Müllerian hormone levels in second allograft donor and recipient. AMH = anti-Müllerian hormone.

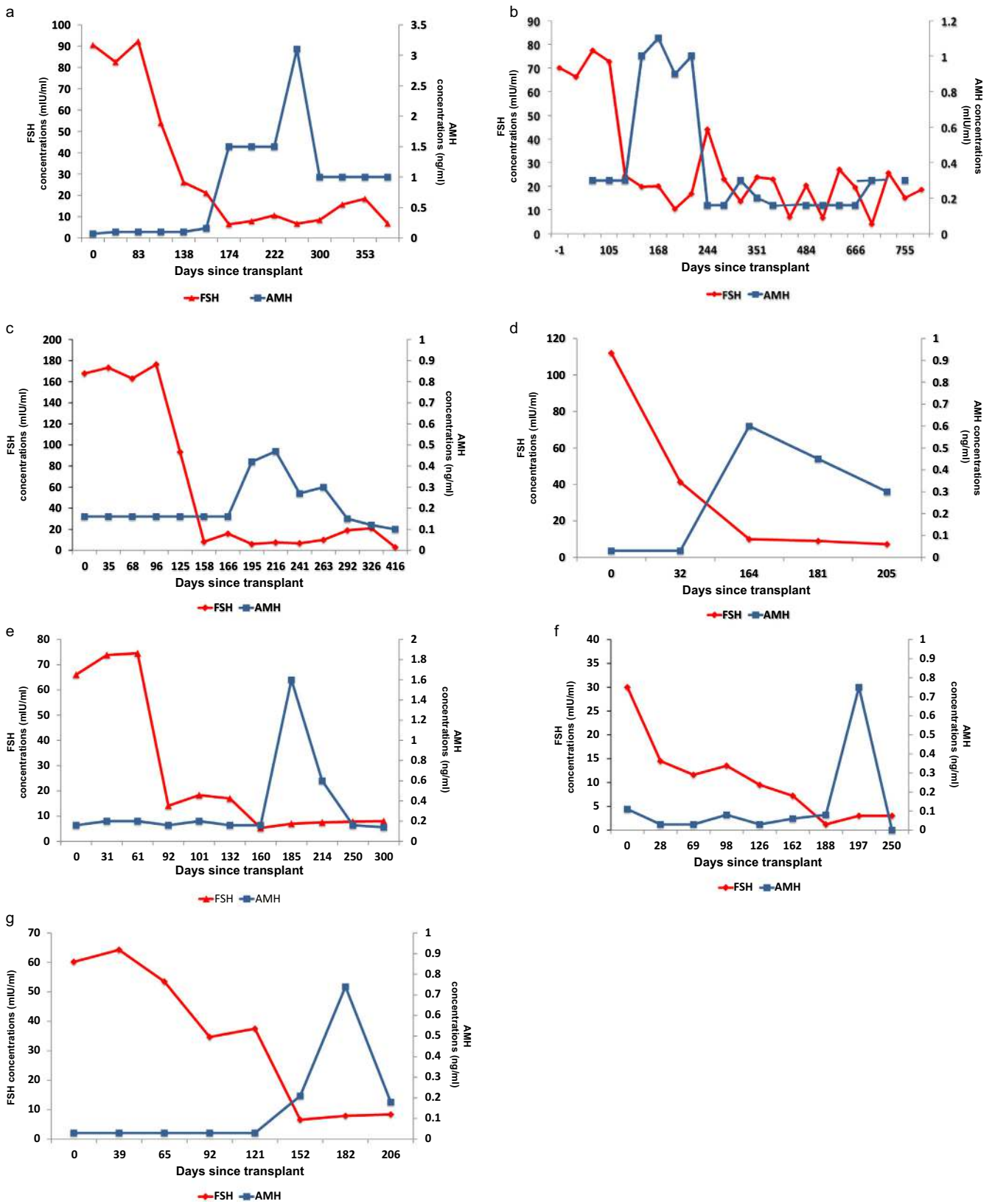


Figure 3 Levels of FSH and anti-Müllerian hormone levels after ovary transplant. AMH = anti-Müllerian hormone.

absence of histological damage from cryopreservation (Kagawa et al., 2009; Keros et al., 2009; Silber et al., 2010). As with fresh ovary transplants, FSH levels returned to normal by about 150 days in all cases, and menstrual cycles resumed shortly before that. The return to normal did not differ between slow-freeze cases and vitrification cases. In all of the cryopreserved cases, just as with fresh transplants, AMH rose to high levels shortly after FSH returned to normal, at around 130–170 days (Figure 3a–g). Then, exactly as with fresh transplant cases, AMH dropped to a lower baseline level by about 240 days and remained at that lower level (Figure 3a–g) (Andersen et al., 2012).

Eight of the 11 cryopreserved autotransplant recipients had a follow-up of over 1 year, which allowed the assessment of pregnancy potential. Seven of these eight patients spontaneously conceived, although one spontaneously aborted (Table 2). The other six were healthy singleton pregnancies. Therefore, cryopreserved and fresh transplantation were similar in hormonal function and high pregnancy outcome. Functional hormonal results thus far have demonstrated a remarkable degree of repeatable concordance in all 22 cases of fresh ovary donor transplantation and cryopreserved ovary autotransplantation.

Discussion

This study provides an unusual opportunity to compare fresh ovarian tissue transplantation cryopreserved autotransplantation in humans in a single centre using the same uniform technique. We began freezing ovaries for cancer patients in 1997, and our first fresh donor ovary transplant was reported in 2005, after the first successful cryopreserved transplant was described in 2004 (Donnez et al., 2004; Silber et al., 2005). It requires a long time for many women to come back for the transplant, and so there is a long delay in reporting any results of cryopreserved ovary autografts. Patients must be relatively sure they are cured of cancer, as well as have a partner and be ready to start a family. In all cases of cryopreserved autotransplantation, just as in fresh transplants, a robust return of menstrual cycling and normal ovarian function was observed at almost precisely the same time after surgery (4.5 months) in all recipients. Six healthy babies born to eight recipients of cryopreserved tissue, along with 11 healthy babies born to 11 recipients of fresh ovary transplants, verify the reliability of this ovary transplant technology. According to numerous scattered reports, 37 or more healthy babies have thus far been delivered to otherwise sterile cancer survivors via cryopreserved ovary transplants (Andersen et al., 2012; Donnez et al., 2011, 2013; Stoop et al., 2014). Egg cryopreservation also has great potential to preserve fertility, but ovary cryopreservation is the only alternative for prepubertal girls; furthermore, ovary cryopreservation does not delay the initiation of cancer treatment as egg cryopreservation might (Homburg et al., 2009). In the future, in addition to cancer patients, ovary tissue cryopreservation may preserve the fertility of healthy younger women against the natural decline in fertility caused by ageing (Andersen et al., 2012; Homburg et al., 2009; Silber et al., 2010; Stoop et al., 2014).

There could be a possible similarity between resting follicle recruitment in the adult and oocyte arrest in the early

Table 2 Pregnancy after cryopreserved ovary autografts.^a

Days of ovarian function	Date of transplant	Date of first menstruation after ovarian transplant	Diagnosis	Spontaneous abortion	Baby born	Girl	Boy
804 ^a	6 March 2007	19 September 2008 ^b	Premature ovarian failure		1	1	
884 ^a	13 January 2009	7 June 2009	Hodgkins		1		1
997 ^a	9 June 2009	28 November 2009	Premature ovarian failure	1	0		
1155 ⁺ ^a	17 June 2011	5 November 2011	Hodgkins		0		
564 ⁺ ^a	12 October 2012	2 March 2013	Multiple sclerosis		1	1	
487 ⁺ ^a	29 March 2013	5 July 2013	Premature ovarian failure		1	1	
496 ⁺ ^a	5 April 2013	27 December 2013	Brain cancer		1		1
502 ⁺ ^a	12 April 2013	1 January 2014	Blood disorder		1		1
328 ⁺	1 October 2013	19 December 2013	Synovial sarcoma		0		
294 ⁺	7 October 2013	6 March 2014	All		0		
306 ⁺	23 October 2013	29 December 2013	Breast cancer		0		
Total				1	6	3	3

^aEight patients had over 1-year follow-up.

^bThree patients had less than 1-year follow up.

embryo. Primordial follicles are not subject to hormonal stimulation; instead, up to 1000 (out of up to 400,000) begin to develop each month regardless of hormonal cycling. Just how they are recruited to develop, and how quickly, into secondary and antral follicles that are sensitive to hormonal stimulation remains to be determined (Anderson et al., 2008; Byskov et al., 1997; Koubova et al., 2006; DB Lesch, personal communication, 2014; Rajah et al., 1992).

Roughly in line with Gougeon's predictions (Gougeon, 1986), in our 22 cases of ovarian transplant, whether fresh or cryopreserved, menstrual cycling returned at 130 to 170 days, day 3 FSH returned to normal at around 150 days, and AMH levels rose at around 170 days to high, above normal, levels and then decreased below normal levels at around 240 days. This pattern indicates that shortly after the cortical graft was placed, a massive recruitment of 'resting' follicles occurred and depleted a large number of eggs from the graft. Then after full return of normal tissue pressure, the AMH stabilized, and a normal rate of recruitment resumed. The question of how these ovary grafts can last so long and result in spontaneous healthy pregnancies despite low AMH, as well as the massive increase in AMH and massive resting follicle recruitment from the ovarian transplant in the recipient between 140 and 240 days after the transplant, is ripe for further research.

In conclusion, no difference was found in clinical and functional results between fresh and cryopreserved ovary cortical grafts, and both demonstrated a high success rate in preserving fertility as well as endocrine function for long periods of time. Therefore, aside from the benefit of fertility preservation for cancer patients, this procedure offers the benefit of relief from menopause without having to resort to exogenous hormone replacement (Andersen et al., 2012).

Acknowledgements

The authors would like to express their gratitude to Dr Bluma Lesch of the Page Lab at MIT for her insightful help interpreting and correlating the pathology, to Helen Skaletsky for statistical advice, and Christina Usher for preparation of manuscript.

References

- Andersen, C.Y., Rosendahl, M., Byskov, A.G., Loft, A., Ottosen, C., Dueholm, M., Schmidt, K.L., Andersen, A.N., Ernst, E., 2008. Two successful pregnancies following autotransplantation of frozen/thawed ovarian tissue. *Hum. Reprod.* 23, 2266–2272.
- Andersen, C.Y., Silber, S.J., Bergholdt, S.H., Jorgensen, J.S., Ernst, E., 2012. Long-term duration of function of ovarian tissue transplants: case reports. *Reprod. Biomed. Online* 25, 128–132.
- Anderson, E.L., Baltus, A.E., Roepers-Gajadien, H.L., Hassold, T.J., De Rooij, D.G., Van Pelt, A.M., Page, D.C., 2008. Stra8 and its inducer, retinoic acid, regulate meiotic initiation in both spermatogenesis and oogenesis in mice. *Proc. Natl. Acad. Sci. U.S.A.* 105, 14976–14980.
- Aydin, Y., Celiloglu, M., Koyuncuoglu, M., Ulukus, C., 2010. Follicular dynamics and apoptosis following unilateral oophorectomy. *Syst. Biol. Reprod. Med.* 56, 311–317.
- Baird, D.T., Webb, R., Campbell, B.K., Harkness, L.M., Gosden, R.G., 1999. Long-term ovarian function in sheep after ovariectomy and transplantation of autografts stored at -196°C . *Endocrinology* 140, 462–471.
- Byskov, A.G., Guoliang, X., Andersen, C.Y., 1997. The cortex-medulla oocyte growth pattern is organized during fetal life: an in-vitro study of the mouse ovary. *Mol. Hum. Reprod.* 3, 795–800.
- Cobo, A., Domingo, J., Perez, S., Crespo, J., Remohi, J., Pellicer, A., 2008. Vitriification: an effective new approach to oocyte banking and preserving fertility in cancer patients. *Clin. Transl. Oncol.* 10, 268–273.
- Deanesly, R., 1954. Immature rat ovaries grafted after freezing and thawing. *J. Endocrinol.* 11, 197–200.
- Demeestere, I., Simon, P., Englert, Y., Delbaere, A., 2003. Preliminary experience of ovarian tissue cryopreservation procedure: alternatives, perspectives and feasibility. *Reprod. Biomed. Online* 7, 572–579.
- Demeestere, I., Simon, P., Moffa, F., Delbaere, A., Englert, Y., 2010. Birth of a second healthy girl more than 3 years after cryopreserved ovarian graft. *Hum. Reprod.* 25, 1590–1591.
- Dittrich, R., Lotz, L., Keck, G., Hoffmann, I., Mueller, A., Beckmann, M.W., Van Der Ven, H., Montag, M., 2012. Live birth after ovarian tissue autotransplantation following overnight transportation before cryopreservation. *Fertil. Steril.* 97, 387–390.
- Donnez, J., Dolmans, M.M., Demylle, D., Jadoul, P., Pirard, C., Squifflet, J., Martinez-Madrid, B., Van Langendonck, A., 2004. Livebirth after orthotopic transplantation of cryopreserved ovarian tissue. *Lancet* 364, 1405–1410.
- Donnez, J., Silber, S., Andersen, C.Y., Demeestere, I., Piver, P., Meirow, D., Pellicer, A., Dolmans, M.M., 2011. Children born after autotransplantation of cryopreserved ovarian tissue. a review of 13 live births. *Ann. Med.* 43, 437–450.
- Donnez, J., Dolmans, M.M., Pellicer, A., Diaz-Garcia, C., Sanchez Serrano, M., Schmidt, K.T., Ernst, E., Luyckx, V., Andersen, C.Y., 2013. Restoration of ovarian activity and pregnancy after transplantation of cryopreserved ovarian tissue: a review of 60 cases of reimplantation. *Fertil. Steril.* 99, 1503–1513.
- Faddy, M.J., Gosden, R.G., Gougeon, A., Richardson, S.J., Nelson, J.F., 1992. Accelerated disappearance of ovarian follicles in mid-life: implications for forecasting menopause. *Hum. Reprod.* 7, 1342–1346.
- Gosden, R.G., Telfer, E., Faddy, M.J., Brook, D.J., 1989. Ovarian cyclicity and follicular recruitment in unilaterally ovariectomized mice. *J. Reprod. Fertil.* 87, 257–264.
- Gosden, R.G., Baird, D.T., Wade, J.C., Webb, R., 1994. Restoration of fertility to oophorectomized sheep by ovarian autografts stored at -196°C . *Hum. Reprod.* 9, 597–603.
- Gougeon, A., 1986. Dynamics of follicular growth in the human: a model from preliminary results. *Hum. Reprod.* 1, 81–87.
- Homburg, R., Van der Veen, F., Silber, S.J., 2009. Oocyte vitrification – women's emancipation set in stone. *Fertil. Steril.* 91, 1319–1320.
- Kaaijk, E.M., Hamerlynck, J.V., Beek, J.F., Van der Veen, F., 1999. Clinical outcome after unilateral oophorectomy in patients with polycystic ovary syndrome. *Hum. Reprod.* 14, 889–892.
- Kagawa, N., Silber, S., Kuwayama, M., 2009. Successful vitrification of bovine and human ovarian tissue. *Reprod. Biomed. Online* 18, 568–577.
- Kawamura, K., Cheng, Y., Suzuki, N., Deguchi, M., Sato, Y., Takae, S., Ho, C.H., Kawamura, N., Tamura, M., Hashimoto, S., Sugishita, Y., Morimoto, Y., Hosoi, Y., Yoshioka, N., Ishizuka, B., Hsueh, A.J., 2013. Hippo signaling disruption and Akt stimulation of ovarian follicles for infertility treatment. *Proc. Natl. Acad. Sci. U.S.A.* 110, 17474–17479.
- Keros, V., Xella, S., Hulthenby, K., Pettersson, K., Sheikhi, M., Volpe, A., Hreinsson, J., Hovatta, O., 2009. Vitriification versus controlled-rate freezing in cryopreservation of human ovarian tissue. *Hum. Reprod.* 24, 1670–1683.
- Kim, S.S., 2003. Ovarian tissue banking for cancer patients. To do or not to do? *Hum. Reprod.* 18, 1759–1761.
- Koskas, M., Uzan, C., Gouy, S., Pautier, P., Lhomme, C., Haie-Meder, C., Duvillard, P., Morice, P., 2011. Fertility determinants after conservative surgery for mucinous borderline tumours of

- the ovary (excluding peritoneal pseudomyxoma). *Hum. Reprod.* 26, 808–814.
- Koubova, J., Menke, D.B., Zhou, Q., Capel, B., Griswold, M.D., Page, D.C., 2006. Retinoic acid regulates sex-specific timing of meiotic initiation in mice. *Proc. Natl. Acad. Sci. U.S.A.* 103, 2474–2479.
- La Marca, A., Giulini, S., Tirelli, A., Bertucci, E., Marsella, T., Xella, S., Volpe, A., 2007. Anti-Mullerian hormone measurement on any day of the menstrual cycle strongly predicts ovarian response in assisted reproductive technology. *Hum. Reprod.* 22, 766–771.
- Lass, A., Paul, M., Margara, R., Winston, R.M., 1997. Women with one ovary have decreased response to GnRH α /HMG ovulation protocol in IVF but the same pregnancy rate as women with two ovaries. *Hum. Reprod.* 12, 298–300.
- Meirow, D., Levron, J., Eldar-Geva, T., Hardan, I., Fridman, E., Zalel, Y., Schiff, E., Dor, J., 2005. Pregnancy after transplantation of cryopreserved ovarian tissue in a patient with ovarian failure after chemotherapy. *N. Engl. J. Med.* 353, 318–321.
- Meredith, S., Dudenhofer, G., Butcher, R.L., Lerner, S.P., Walls, T., 1992. Unilateral ovariectomy increases loss of primordial follicles and is associated with increased metestrous concentration of follicle-stimulating hormone in old rats. *Biol. Reprod.* 47, 162–168.
- Nagy, Z.P., Chang, C.C., Shapiro, D.B., Bernal, D.P., Kort, H.I., Vajta, G., 2009. The efficacy and safety of human oocyte vitrification. *Semin. Reprod. Med.* 27, 450–455.
- Newton, H., Aubard, Y., Rutherford, A., Sharma, V., Gosden, R., 1996. Low temperature storage and grafting of human ovarian tissue. *Hum. Reprod.* 11, 1487–1491.
- Oktay, K., Economos, K., Kan, M., Rucinski, J., Veeck, L., Rosenwaks, Z., 2001. Endocrine function and oocyte retrieval after autologous transplantation of ovarian cortical strips to the forearm. *JAMA* 286, 1490–1493.
- Parrott, D.M., 1960. The fertility of mice with orthotopic ovarian grafts derived from frozen tissue. *J. Reprod. Fertil.* 1, 230–241.
- Poirot, C., Abirached, F., Prades, M., Coussieu, C., Bernaudin, F., Piver, P., 2012. Induction of puberty by autograft of cryopreserved ovarian tissue. *Lancet* 379, 588.
- Rajah, R., Glaser, E.M., Hirshfield, A.N., 1992. The changing architecture of the neonatal rat ovary during histogenesis. *Dev. Dyn.* 194, 177–192.
- Revel, A., Laufner, N., Ben Meir, A., Lebovich, M., Mitrani, E., 2011. Micro-organ ovarian transplantation enables pregnancy: a case report. *Hum. Reprod.* 26, 1097–1103.
- Revelli, A., Marchino, G., Dolfin, E., Molinari, E., Delle Piane, L., Salvagno, F., Benedetto, C., 2013. Live birth after orthotopic grafting of autologous cryopreserved ovarian tissue and spontaneous conception in Italy. *Fertil. Steril.* 99, 227–230.
- Saiduddin, S., Rowe, R.F., Casida, L.E., 1970. Ovarian follicular changes following unilateral ovariectomy in the cow. *Biol. Reprod.* 2, 408–412.
- Sanchez, M., Alama, P., Gadea, B., Soares, S.R., Simon, C., Pellicer, A., 2007. Fresh human orthotopic ovarian cortex transplantation: long-term results. *Hum. Reprod.* 22, 786–791.
- Silber, S., Kagawa, N., Kuwayama, M., Gosden, R., 2010. Duration of fertility after fresh and frozen ovary transplantation. *Fertil. Steril.* 94, 2191–2196.
- Silber, S., Silber, D., Barbey, N., 2012. Long-term function of ovarian tissue transplants. *Middle East Fertil. Soc. J.* 17, 215–220.
- Silber, S.J., 2013. Transplantation of ovarian tissue or immature oocytes to preserve and restore fertility in humans. In: Gosden, R.G. (Ed.), *Biology and Pathology of the Oocyte*. Cambridge University Press, Cambridge, UK, pp. 430–442.
- Silber, S.J., Gosden, R.G., 2007. Ovarian transplantation in a series of monozygotic twins discordant for ovarian failure. *N. Engl. J. Med.* 356, 1382–1384.
- Silber, S.J., Lenahan, K.M., Levine, D.J., Pineda, J.A., Gorman, K.S., Friez, M.J., Crawford, E.C., Gosden, R.G., 2005. Ovarian transplantation between monozygotic twins discordant for premature ovarian failure. *N. Engl. J. Med.* 353, 58–63.
- Silber, S.J., Derosa, M., Pineda, J., Lenahan, K., Grenia, D., Gorman, K., Gosden, R.G., 2008a. A series of monozygotic twins discordant for ovarian failure: ovary transplantation (cortical versus microvascular) and cryopreservation. *Hum. Reprod.* 23, 1531–1537.
- Silber, S.J., Grudzinskas, G., Gosden, R.G., 2008b. Successful pregnancy after microsurgical transplantation of an intact ovary. *N. Engl. J. Med.* 359, 2617–2618.
- Stern, C.J., Gook, D., Hale, L.G., Agresta, F., Oldham, J., Rozen, G., Jobling, T., 2013. First reported clinical pregnancy following heterotopic grafting of cryopreserved ovarian tissue in a woman after a bilateral oophorectomy. *Hum. Reprod.* 28, 2996–2999.
- Stoop, D., Cobo, A., Silber, S.J., 2014. Fertility preservation for age related fertility decline. *Lancet* 384, 1311–1319.
- Yasui, T., Hayashi, K., Mizunuma, H., Kubota, T., Aso, T., Matsumura, Y., Lee, J.S., Suzuki, S., 2012. Factors associated with premature ovarian failure, early menopause and earlier onset of menopause in Japanese women. *Maturitas* 72, 249–255.
- Zhai, A., Axt, J., Hamilton, E.C., Koehler, E., Lovvorn, H.N., 3rd, 2012. Assessing gonadal function after childhood ovarian surgery. *J. Pediatr. Surg.* 47, 1272–1279.

Declaration: The authors report no financial or commercial conflicts of interest.

Received 10 September 2014; refereed 12 February 2015; accepted 17 February 2015.