Microsurgery for the Undescended Testicle

*Sherman J. Silber, M.D., F.A.C.S.**

There has been considerable discussion recently about how best to localize a nonpalpable cryptorchid testis (spermatic venography, EMI scan, or spermatic arteriography), and much debate about proper surgical management of the testis that is high and intraperitoneal.[6, 10, 13, 15, 21, 30] In our view there is no longer a need for controversy. Laparoscopy is the simplest, safest, and most reliable method of localizing high intra-abdominal testes.[7] For surgical management, the spermatic vessels must be divided in order to bring the testicle into the scrotum, but the collateral blood supply via the deferential artery is not reliable.[9] In many cases there is a risk of testicular atrophy.

We have recently seen six patients with bilateral intra-abdominal testes who had undergone division of the spermatic vessels with microsurgical reanastomosis to the inferior epigastric vessels on one side, and simple division without reanastomosis on the other.[25, 27] On the side where revascularization of the spermatic vessels had been performed, the testis retained its normal size and texture. On the side where the vessels had simply been divided without reanastomosis, partial or complete testicular atrophy occurred. Martin has made similar observations.[14]

RATIONALE

The controversies concerning the problem of intra-abdominal testes fall into two major categories. First, does it make any sense to attempt to treat these intraperitoneal testes surgically? Second, if there is a rationale for such treatment, what is the safest surgical approach?

The danger of unrecognized cancer in the intra-abdominal testicle has already been dealt with in detail, and certainly provides one motive for placing such a testicle in the scrotum or possibly removing it.[5, 16] Furthermore, the intra-abdominal testis is easily subject to possible torsion, which could present as severe, acute pain in the abdomen.[22]

It has been assumed generally that the cryptorchid testicle suffered only a loss of spermatogenic function; hormonal function supposedly was unaltered. However, recent studies have demonstrated that the abdominal environment also affects the endocrine function of the testis, and will result in premature loss of the production of testosterone. Patients with cryptorchidism have impaired intratesticular production of androgens. An adult with untreated bilateral cryptorchidism will have an elevated level of luteinizing hormone (LH), and will have premature loss of the secretion of testosterone.[2, 7, 22] Experimental studies in the rat have demonstrated that when scrotal testes are transferred to the abdomen, there is an immediate and dramatic elevation in follicle-stimulating hormone (FSH), corresponding to a rapid deterioration of spermatogenesis.[1] However, over a longer period of time the level of LH also begins to increase, indicating a later loss of endocrine function of the cryptorchid testes. The intra-abdominal environment is detrimental not only to spermatogenesis, but also to the production of hormones. It simply takes longer for this aspect of testicular function to deteriorate.

The question of whether transplantation of these testes to the scrotum of a child will provide for the development of fertility when the child grows up has now been answered also. There is overwhelming experimental evi-

*Consultant in Urology and Microsurgery, St. Luke's West Hospital, St. Louis, Missouri

dence that a surgically created cryptorchid testis will have diminished spermatogenesis and that replacement of the cryptorchid testis into the scrotum will allow for the recovery of spermatogenesis.[11, 12, 17, 21, 28]

There are documented case reports of azoospermic adults (16 to 25 years of age) with bilateral simple cryptorchidism who after orchiopexy developed normal spermatogenesis and reasonable sperm counts.[4, 8] Although these were not intra-abdominal cases, they lend support to the notion that cryptorchid testes can make sperm if they are transferred to the scrotum. We now have a well-documented case (see Case 7 in this article) demonstrating that even intra-abdominal testes will develop normal spermatogenesis if they are properly transferred to the scrotum without damaging the blood supply.[26]

The second controversial question concerns the safest method for transferring the high intraperitoneal testis into the scrotum. The concept of simply dividing the internal spermatic vessels is not new. Bevan first recommended this approach in 1903.[3] Both he and Moschowitz reported good results.[19] However, Mixter (in 1924) and Wangenstein (in 1927), as well as MacCollum (in 1935) reported uniformly poor results with the Bevan operation.[18, 20, 29]

In 1963 Fowler and Stephens were the first to demonstrate that by dividing the internal spermatic vessels farther up and not dissecting their attachment to the cord, it was possible to preserve collateral circulation via the deferential artery.[9] The spermatic vessels could be clamped first and then the testicle biopsied to determine the adequacy of collateral blood flow. Even in their experience, almost half of the patients underwent some testicular atrophy, and a third underwent rather severe atrophy. Furthermore, the original diagrams of Fowler and Stephens demonstrate that their technique was most valuable in the management of the so-called "long-looped vas," when the testis is really located at the level of the internal inguinal ring and the vas deferens loops down in the canal toward the external ring and then comes back to the testis at the internal ring. By avoiding dissection in the inguinal canal the collateral circulation can be preserved. Most of the cases Fowler and Stephens described did not involve severely high intra-abdominal testes. Brendler, Clatworthy et al., and Gibbons et al. have all resorted to the Fowler-Stephens procedure for the high intraperitoneal testes.[6, 10, 27] Instances of atrophy have been reported by all groups utilizing this approach.

In our experience the deferential blood supply to the testicle cannot be relied upon, and previous reports about the good results of dividing the spermatic vessels without reanastomosis are overoptimistic. In 1949, Harrison demonstrated in fresh autopsy dissections that the sum of the diameters of the deferential and cremasteric arteries was equal to the diameter of the testicular artery in only one third of cases, indicating that adequate functional collateral circulation to the testis is by no means universal.[23, 28] Furthermore, observations in patients who underwent ligation of the spermatic artery at the time of varicocelectomy or inadvertently at the time of childhood inguinal herniorrhaphy have demonstrated to us that collateral circulation to the testes is by no means secure, and in most cases it will not be sufficient to nourish the testes adequately after ligation of the spermatic vessels.[25]

MICROSURGICAL TECHNIQUE

Microvascular Scoville-Lewis, Schwartz, or Heifetz neurosurgical clips are placed on the deep inferior epigastric artery and both superficial and deep inferior epigastric veins inferiorly. These vessels are then tied off superiorly. Although blood flow through the epigastric vessels is adequate in either direction, one can rely on better arterial pressure and better venous drainage inferiorly, since these vessels are direct branches of the external iliac artery. The inferior epigastric vessels are each divided and the lumens examined. The spermatic vessels are then brought into the area for anastomosis (Fig. 1).

There will usually be one or two spermatic veins and one spermatic artery. The one spermatic artery is about one third the size of the spermatic vein and is generally too small to be anastomosed to the deep inferior epigastric artery unless it is spatulated. This is no problem, however. The spermatic artery is spatulated dorsally to create a triangular opening that will allow its diameter to match the diameter of the deep inferior epigastric artery (Fig. 2). The arterial anastomosis is performed first.

For this anastomosis, 9-0 or 10-0 nylon on a BV-6, BV-2, or GS-16 needle is ideal. The first suture is placed in the apex of the spatulation on the spermatic artery from outside to

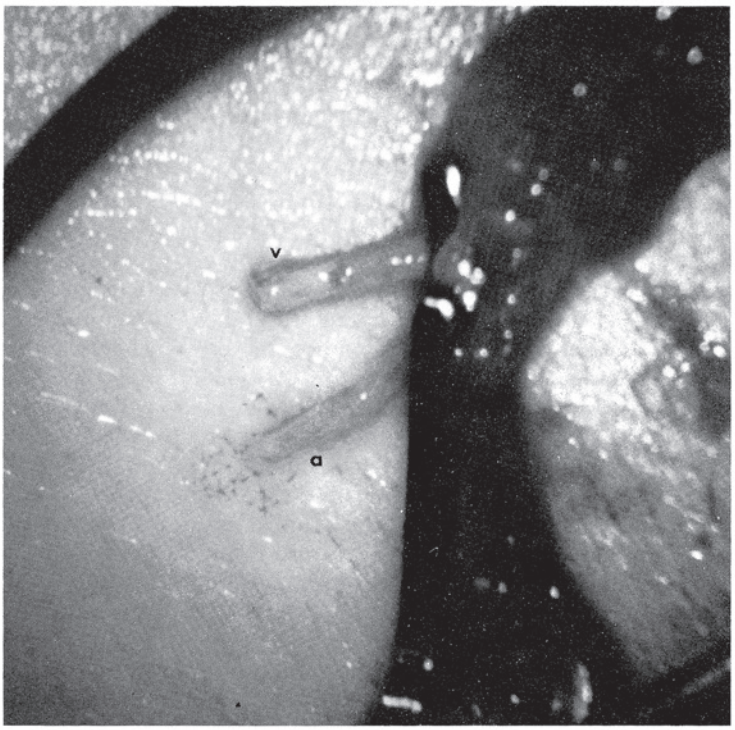

Figure 1. The divided spermatic vein (v) and artery (a).

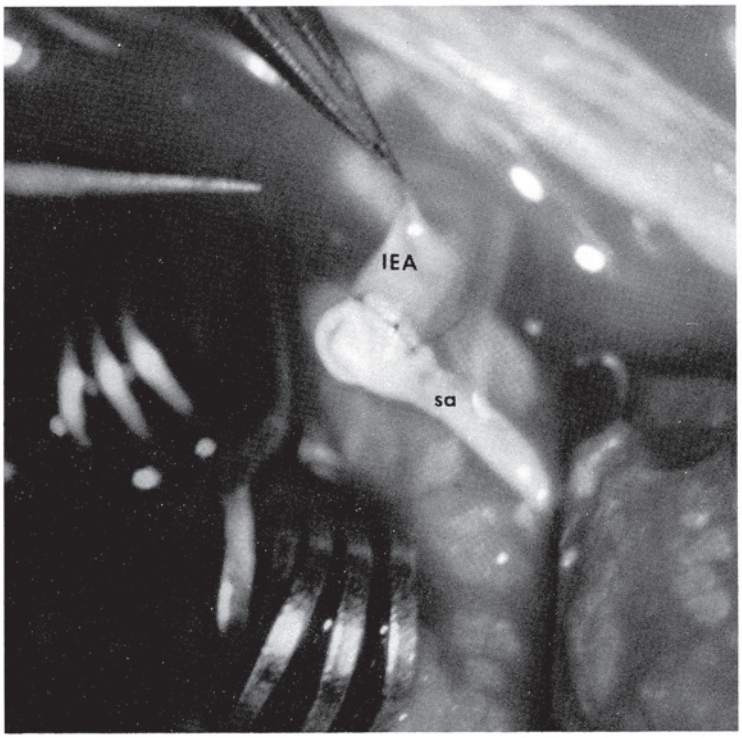

Figure 2. The spermatic artery (sa) must be spatulated to allow anastomosis to the inferior epigastric artery (IEA).

inside and then is carried through to the anterior 12 o'clock position of the deep inferior epigastric artery from inside to outside. The suture is tied down and one end is left 2 cm long as a stay suture for manipulation. The next suture is placed at one or the other of the corners of the spatulated spermatic artery and carried through to a position 120 degrees from the first suture in the inferior epigastric artery. This is also tied. Several sutures are then placed between these two initial stay sutures. This represents an anastomosis of one third of the vessel's diameter.

Next, the stay sutures are used to rotate the vessels so that the unsutured portion of the anastomosis is now in the anterior position. The next stay suture is placed at the corner of the other spatulated edge of the spermatic artery, outside to inside, and then from inside to outside in the inferior epigastric artery, again 120 degrees away from the original anterior suture. Similarly, this stay suture is left 2 cm long for easy manipulation, and several sutures are placed between it and the original anterior suture. Now two thirds of the arterial anastomosis has been completed. The two most lateral stay sutures are then used to completely rotate the vessel 180 degrees, exposing the remaining 120 degrees of unsutured vessel wall. Usually two or three more sutures are adequate to complete the anastomosis in this portion. When the anastomosis is complete, all stay sutures can be divided (Fig. 3). Strict adherence to a methodical pattern such as this is important; otherwise one will fairly soon find oneself confused as to what portion of the donor artery goes to what portion of the recipient artery.

Interrupted sutures are absolutely critical. Continuous suturing will result in a purse-string effect, in bunching, and, at best, in a confusing, and at worst, an obstructed, anastomosis. The interrupted sutures should be tied down and cut as they are placed, rather than leaving them to be tied down at the end. The latter will create an impossible puppet show, in which the spider-web-thin sutures will become entangled with each other before even half of them have been placed. No attempt should be made to perform the arterial anastomosis until the spatulation has been performed as described, because the discrepancy between the lumens is otherwise too great.

Contrary to the procedure usually used in other sorts of transplantations, the arterial microclamp may be taken off prior to any venous anastomosis and the testicle allowed to become perfused. There may be a tiny amount of arterial suture line bleeding at first, but patient application of a sponge for a few minutes should control it. One should be very

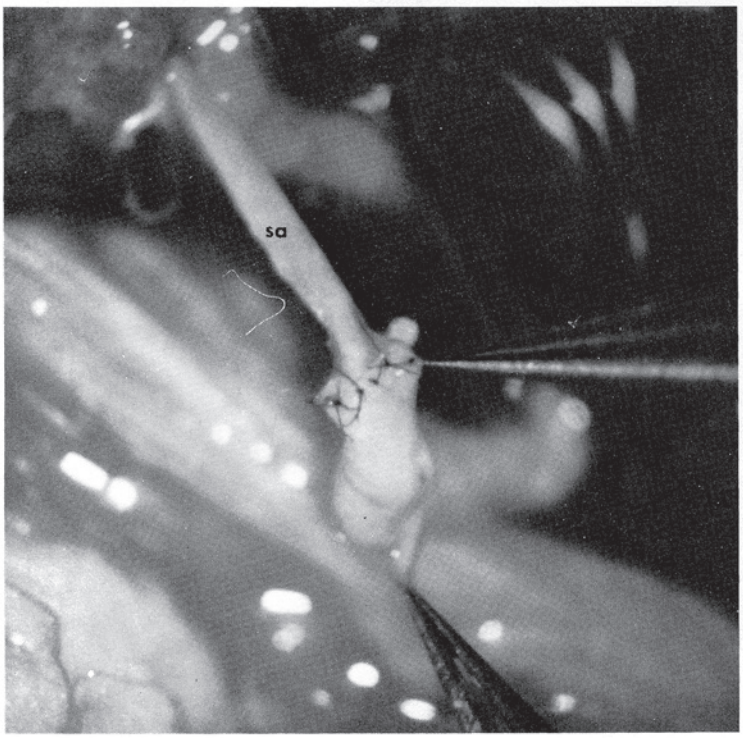

Figure 3. Completed anastomosis of spermatic artery (sa).

cautious about placing an extra stitch in a bleeding area of the anastomosis, as is commonly done in macrovascular surgery. Usually any bleeding will stop with the application of a sponge for a few minutes, and any suture placed in haste in such a delicate anastomosis will often result in obstruction. The arterial clamp can be removed before any venous anastomosis is performed because even in a testicle with excellent blood supply, the flow is small enough that blood loss via the venous outflow will not seriously affect the patient's condition. In the meantime the ischemic period is considerably reduced by such a maneuver.

The two spermatic veins have freely anastomotic circulation, and therefore one of these veins can be clamped with a microvascular clamp in preparation for anastomosis to the deep inferior epigastric vein while the other spermatic vein is allowed to bleed freely. After the first venous anastomosis to the deep inferior epigastric vein is performed, the microvascular clamps can be removed from both the spermatic vein and the deep inferior epigastric vein and a clamp placed on the extra spermatic vein, which has been bleeding all this time, to prepare it for anastomosis to the superficial inferior epigastric vein. Now there is one adequate venous channel, so we still do not have to worry about congestion of the testis from venous occlusion during either of these venous anastomoses.

The technique for the venous anastomosis is somewhat simpler. Since the vessel sizes here will generally match up very nicely, spatulation is not necessary. A standard anastomosis can be performed by placing two anterior stitches 120 degrees apart. Several sutures can be placed between these two initial stay sutures, and the entire vessel is then rotated 180 degrees so that the posterior 240 degrees that have not been sutured yet are facing anteriorly (Fig. 4). Another stay suture is placed halfway, dividing this into two 120-degree segments, each of which will require several sutures in between to complete the anastomosis (Fig. 5).

Patency of the arterial anastomosis is generally checked by observing excellent venous outflow and also can usually be observed under the microscope directly. Patency of the venous anastomosis can be ascertained by a prompt filling of the clamped venous segment across the anastomosis when the clamp on the spermatic vein is removed. Following this, the clamp on the inferior epigastric vein is removed. The testicle has now been completely revascularized; it can be placed into the scrotal sac without any tension (Fig. 6). Adequacy of blood flow to the testis both intraoperatively and postoperatively is monitored with a Doppler probe.

In cases of bilateral cryptorchidism in which we reanastomosed the divided spermatic vessels on one side but relied on collateral cir-

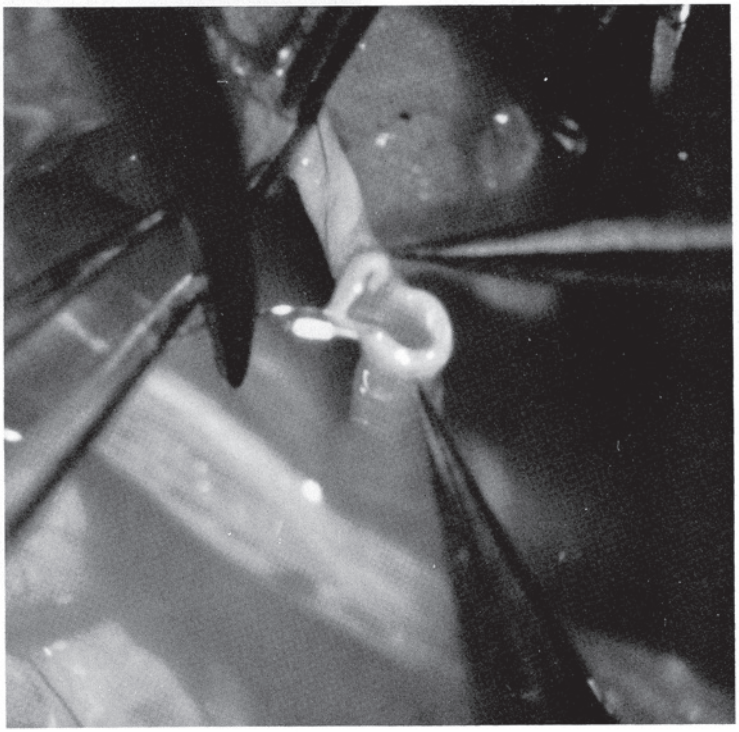

Figure 4. Venous anastomosis after the first 120 degrees have been sutured.

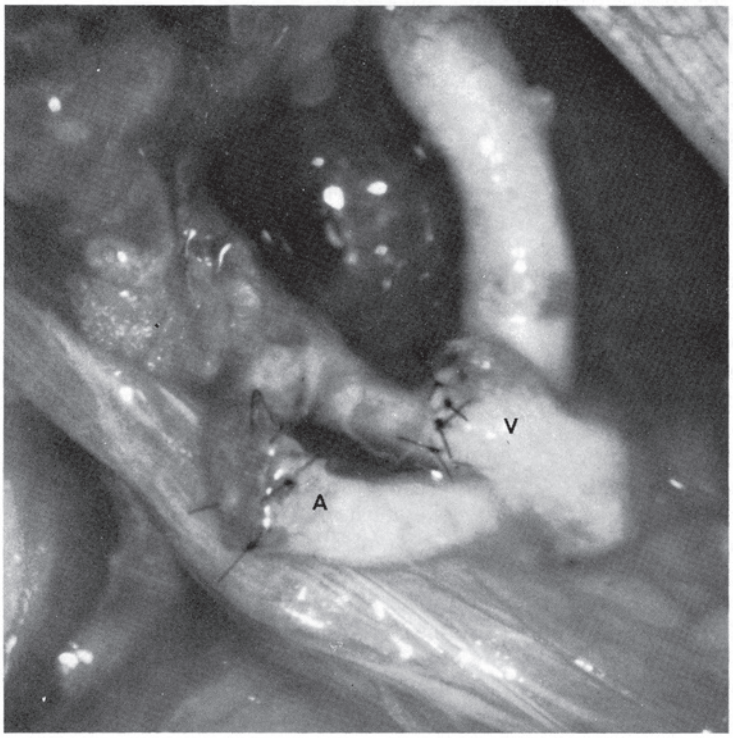

Figure 5. Completed arterial (A) and venous (V) anastomoses.

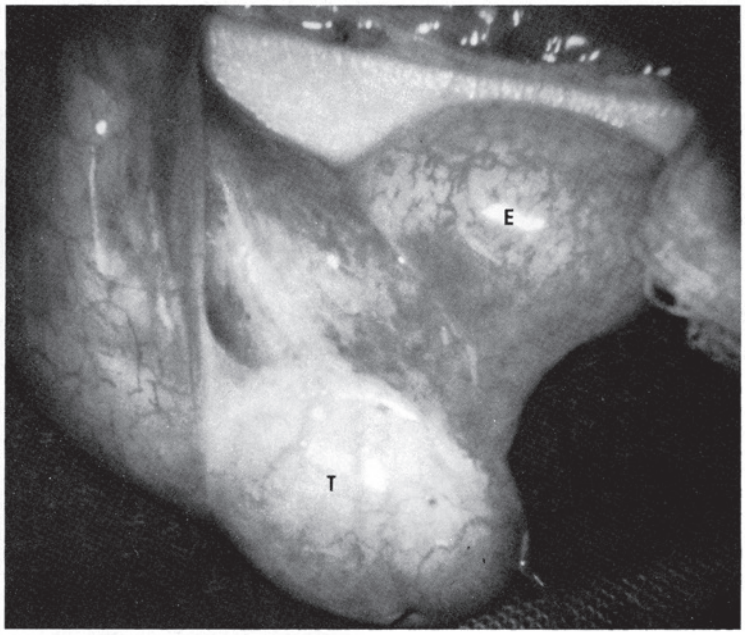

Figure 6. The blanched testicle (T) before vascular clamps are removed, lying on groin but free now to be transferred to scrotum.

culation via the vas deferens on the other side, we have always wished that we had simply revascularized both sides.

REPORT OF SEVEN CASES

Seven patients who had very high intraperitoneal testes were referred to us specifically because of concern that division of the spermatic vessels without reanastomosis might be hazardous for them. Two of the patients (both five years old) had had previous division of the spermatic vessels on one side only, using the Fowler-Stephens technique to bring the high testes into the scrotum, which had resulted in complete atrophy. These two patients were referred to us with only one remaining testicle each, and a history suggesting that simple division of the spermatic vessels without microsurgical reanastomosis might result in its loss. In a third case the patient had undergone no previous attempt at orchiopexy, but since he was 21 years of age, had had normal postpubertal development, and had heavy abdominal musculature, it was feared that there would be tension on the vas deferens and deferential artery. The fourth patient, a five-year-old boy with very high testes, had not previously undergone any attempt at orchiopexy. The fifth patient, an 11-year-old boy, had undergone an attempt at orchiopexy on one side without division of the spermatic vessels, and the testicle could not be brought beyond the internal ring. The sixth patient, two and a half years of age, appeared at first to have a good result from a simple division of the spermatic vessels without reanastomosis (on one side only), but at six months postoperatively, it was apparent that the original evaluation was incorrect. The testicle was totally atrophied in one year. The seventh patient was 18 years old and had bilateral intra-abdominal testicles; his case answered the question about whether orchiopexy encourages spermatogenesis.

Case 1

A five-year-old boy with nonpalpable undescended testes had undergone bilateral inguinal explorations a year earlier, and no testes had been found in the inguinal canal. An intraperitoneal extension of the incision on each side had demonstrated high intraperitoneal testes. On the right side, the internal spermatic vessels had been clamped and a small incision made in the testis to check for adequacy of the collateral circulation. Bleeding had been observed but had not been brisk. The Fowler-Stephens test was thus felt to be equivocal on the right side, but the vessels had been divided and the testicle then placed in the scrotum. The Fowler-Stephens test on the left was also equivocal, but on this side the vessels had not been divided, and the procedure had been abandoned. Postoperatively over the next three months the right testicle atrophied totally. The patient was then referred to us for autotransplantation of the remaining left testicle.

Laparoscopy revealed an intraperitoneal left testicle apparently tacked down in the area of the internal ring. The internal spermatic vessels were under tension. The vas deferens was not. The abdomen was then opened through a midline intraperitoneal incision. The spermatic vessels were clamped proximally, and a microvascular clamp was placed on the vessels distally. The epigastric vessels were freed inferior to the area of the previous left groin incision. The spermatic artery was spatulated and then anastomosed to the inferior epigastric artery by the technique previously described.[7, 24] Ischemia time was 40 minutes. The testicle was placed in the left scrotal sac with the vas deferens coming just over the pubic symphysis, the shortest possible route. There was no tension on the microvascular anastomosis, but there was a fair degree of tension on the vas deferens and the deferential vessels, which seemed unavoidable.

Postoperatively the patient's course was unremarkable. He was discharged six days later, and on follow-up examination eight months later, the testicle was of normal size and consistency, with no sign of atrophy. A stimulation test with human chorionic gonadotropin (HCG) showed a normal testosterone response, similar to that found preoperatively.

Case 2

A five-year-old child with prune belly syndrome had undergone orchiopexy on the left side at another institution with the Fowler-Stephens procedure, dividing the spermatic vessels and allowing the testicle to be supplied by the artery of the vas deferens. The vascular pedicle had been divided high and the testis brought down on a long strip of peritoneum that was attached to the vas and its blood

supply. The surgeon had noted that there was still some tension on the vas deferens and collateral vasculature supplying the testes, but that it finally had been anchored satisfactorily in the scrotal pouch in the left scrotum.

Postoperatively the testis was found to be located actually just above the pubic symphysis in the subcutaneous fatty tissue, and not truly in the scrotum. There was partial atrophy as well. It was therefore decided to perform the orchiopexy on the opposite side using microvascular technique.

Laparoscopy demonstrated an intraperitoneal testicle essentially undisturbed. Autotransplantation was accomplished by division of the spermatic vessels with reanastomosis to the inferior epigastric vessels. Postoperatively the testes were in a good position, with no atrophy. There was some tension on the vas deferens, but this did not compromise the blood supply coming from the reanastomosed internal spermatic vessels. Postoperatively the stimulation test with HCG demonstrated a normal testosterone response, as it had preoperatively.

Case 3

A six-year-old boy with no palpable testes and a positive response to a stimulation test with HCG had an EMI scan that revealed the testes to be located very high in the intraperitoneal region. The abdomen was opened through a midline intraperitoneal incision, and two normal-sized testes were located rather high in the region. The Fowler-Stephens maneuver was performed on each side, and free bleeding was noted. The spermatic vessels were then divided and the testes mobilized out of the abdomen without interfering with its collateral blood supply through the deferential artery. However, it was noted that on each side there would be tension on the vas deferens if the testes were brought into the scrotal sac.

On the left side reanastomosis of the vessels was not performed, and the testicle was allowed to remain in the left scrotal sac under some tension, relying on collateral circulation via the deferential artery and vein. On the right side, however, the inferior epigastric artery and veins were anastomosed directly to the divided spermatic vessels by use of microsurgery.

Six months postoperatively, the left testicle had atrophied almost completely and the right testicle was of normal size and consistency. The postoperative stimulation test with HCG showed a normal testosterone response.

Case 4

A 21-year-old man who was about to be married was concerned that he had never noticed testicles in his scrotal sac. He had been turned down by the army for this reason and was seeking consultation. He had undergone normal postpubertal development. Levels of testosterone averaged 315 ng per dl. Follicle-stimulating hormone was essentially at castrate levels (more than 100 μU per ml), and LH was markedly elevated (in the range of 45 to 55 μU per ml). The EMI scan demonstrated two normal-sized testicles located intraperitoneally at about the level of the pelvic brim. Analysis of semen demonstrated azoospermia with a normal semen volume and normal fructose.

Because the patient was concerned about possible development of an intra-abdominal testicular malignancy, as well as the possibility of premature loss of endocrine function of the testicles, he underwent laparotomy.

Two normal-sized testes were located at the pelvic brim, as predicted by EMI scan. The intraperitoneal appearance was similar to that of two normal ovaries in a young woman. The Fowler-Stephens maneuver was performed on each side, and bleeding from the cut tunica albuginea of the testicle was present but equivocal in briskness. Division of the spermatic vessels with microvascular reanastomosis to the inferior epigastric vessels was performed on the right side. On the left side, however, the spermatic vessels were merely divided, and the testicle was brought into the scrotal sac, relying on collateral circulation via the deferential artery and veins, which were properly preserved. There was a great deal of tension on the vas deferens despite the fact that the shortest possible route was used to get the testicle into the scrotum.

Three months postoperatively the left testicle was completely atrophied and the right testicle was of normal size and consistency. Postoperative hormone values were unchanged from preoperative values. Follow-up on this patient extended to six months without any sign of deterioration of the right testicle. Shortly after the last follow-up visit he was killed in an automobile accident.

Case 5

An 11-year-old boy who had bilaterally nonpalpable testes underwent exploration of the left groin with extension of the incision in an attempt to free up and bring down a high intraperitoneal testis on that side. The spermatic vessels were not divided, and the testicle could not be brought below the internal ring. He was then referred to us. Laparoscopy revealed a very high intraperitoneal right testis. The left testis was atrophied and fixed by adhesions at the internal ring. Microvascular autotransplantation was performed on the right. Postoperatively there was no atrophy, and the right testicle was properly located in the scrotum. Right testicular blood flow had been poor after division of the spermatic vessels, but became brisk after revascularization.

Case 6

A two-and-a-half-year-old boy with bilateral intraperitoneal testicles underwent a Fowler-Stephens orchiopexy on the right side at another institution involving division of the internal spermatic vessels. Collateral blood flow via the deferential vessels was considered "adequate." For the first three months postoperatively, the testicle seemed normal in size, but by six months postoperatively, the testicle had shriveled and the scrotal scan revealed poor blood flow.

At five years of age we performed an autotransplant of the remaining left testicle by dividing the internal spermatic vessels and reanastomosing them to the interior epigastrics under the microscope. Postoperative Doppler readings and scrotal scan revealed excellent blood flow, and the testicle remained persistently normal in size and consistency. Interestingly, at the time of our surgery, the blood supply of the right vas deferens looked normal, but was clearly not adequate to nourish that testicle.

Case 7

An 18-year-old boy about to enter college was referred for bilaterally nonpalpable (intra-abdominal) testicles and azoospermia. A groin exploration in childhood had revealed no testicles, but he nonetheless went through normal puberty, and the testicles were obviously intraperitoneal (Fig. 7). He underwent bilateral testicular autotransplantation. The FSH came down to normal levels by 8 months postoperatively, and by 16 months postoperatively he had a sperm count of 15,000,000 per cc with 90 per cent excellent progressive motility. This case demonstrates that these testicles can possibly recover fertility if operated upon properly even in adulthood.

CONCLUSIONS

Preoperative diagnosis and localization of the high intra-abdominal testis is most reliably and easily accomplished by laparoscopy. Placement of these high testicles into the scrotum can best be accomplished by division of the spermatic vessels. Microsurgical reanastomosis to the inferior epigastric vessels is

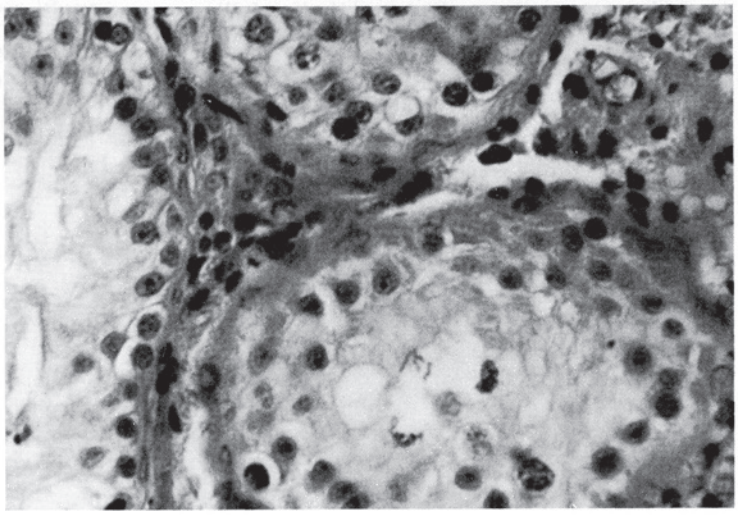

Figure 7. Biopsy of 18-year-old patient's intra-abdominal testis at time of surgery showing no spermatogenesis. Sixteen months after autotransplantation he has normal semen analysis.

recommended to prevent partial or complete testicular atrophy and to maximize the eventual prospect for fertility. Since we know that even some adults with bilateral cryptorchidism can recover fertility after placement of the testis in the scrotum, it is important not to compromise blood supply.

There may be hope for fertility if the original surgery is performed with proper attention to blood supply.

REFERENCES

1. Altwein, J. E., and Gittes, R. F.: Effect of cryptorchidism and castration on FSH and LH levels in the adult rat. Invest. Urol., *10*:167, 1972.
2. Atkinson, P. M., Epstein, M. T., and Rippon, A. E.: Plasma gonadotropins and androgens in the surgically treated cryptorchid patient. J. Pediatr. Surg., *10*:27, 1975.
3. Bevan, A. D.: The surgical treatment of the undescended testicle. J.A.M.A., *41*:718, 1903.
4. Britton, B. J.: Spermatogenesis following bilateral orchidopexy in adult life. Br. J. Urol., *47*:464, 1975.
5. Campbell, H. E.: Incidence of malignant growth of the undescended testicle: A critical and statistical study. Arch. Surg., *44*:353, 1942.
6. Clatworthy, H. W., Hollabaugh, R. S., and Grosfeld, J. L.: The "long loop vas" orchiopexy for the high undescended testis. Amer. Surg., *38*:69, 1972.
7. Cohen, R., and Silber, S. J.: Laparoscopy for cryptorchidism. J. Urol., *124*:928, 1980.
8. Cowhaire, F., Derom, F., and Vermeulen, L.: The recovery of spermatogenesis in an azoospermic patient after operation for bilateral undescended testes at age of 25 years. Int. J. Androl., *1*:117, 1978.
9. Fowler, R., and Stephens, F. D.: The role of testicular vascular anatomy in the salvage of high undescended testes. *In* Stephens, F. D. (ed.): Congenital Malformations of the Rectum, Anus, and Genito-Urinary Tracts. Baltimore, Williams & Wilkins, 1963.
10. Gibbons, M. D., Cromie, W. J., and Duckett, J. W., Jr.: Management of the abdominal undescended testicle. J. Urol., *122*:76, 1979.
11. Hadziselimovic, F., Herzog, B., and Seguchi, H.: Surgical correction of cryptorchidism at two years: Electron microscopic and morphometric investigations. J. Pediatr. Surg., *10*:19, 1975.
12. Kiesewetter, W. B., Shull, W. R., and Fetterman, G. H.: Histologic changes in the testis following the anatomically successful orchidopexy. J. Pediatr. Surg., *4*:59, 1969.
13. Levitt, S. B., Kogan, S. J., Engel, R. M., et al.: The impalpable testis: A rational approach to management. J. Urol., *120*:515, 1978.
14. Martin, D.: Orchiopexy employing microvascular anastomosis: A brief follow-up. Letter of July 22, 1980, to Society for Pediatric Urologists.
15. Martin, D. C.: The undescended testis: Evolving concepts in management. Urol. Dig. J. Contin. Educ. Urol., November 17, 1977.
16. Martin, D. C., and Menck, H. R.: The undescended testis: Management after puberty. J. Urol., *114*:77, 1975.
17. Mengel, W., Hienz, H. A., Sippell, W. G., et al.: Studies on cryptorchidism: A comparison of histologic findings in the germinative epithelium before and after the second year of life. J. Pediatr. Surg., *9*:445, 1974.
18. Mixter, E. G.: Undescended testicle: Operative treatment and end results. Surg. Gynecol. Obstet., *39*:275, 1924.
19. Moschowitz, A. V.: The anatomy and treatment of undescended testes: With special reference to the Bevan operation. Ann. Surg., *52*:821, 1910.
20. McCollum, D. W.: Clinical study of spermatogenesis of undescended testicles. Arch. Surg., *31*:290, 1935.
21. Nelson, W. O.: Mammalian spermatogenesis, effect of experimental cryptorchidism in the rat, and nondescent of the testis in man. Recent Prog. Horm. Res., *6*:29, 1951.
22. Riegler, H. C.: Torsion of the intra-abdominal testis. Surg. Clin. North Am., *52*:371, 1972.
23. Silber, S. J.: Transplantation of human testis for anorchia. Fertil. Steril., *30*:181, 1978.
24. Silber, S. J.: Microsurgery. Baltimore, Williams and Wilkins Co., 1979.
25. Silber, S. J.: The intra-abdominal testis: Microvascular autotransplantation. J. Urol., *125*:329, 1981.
26. Silber, S. J.: Recovery of spermatogenesis after testicle autotransplantation in an adult male. Fertil. Steril. In press.
27. Silber, S. J., and Kelly, J.: Successful auto-transplantation of an intra-abdominal testis to the scrotum by microvascular technique. J. Urol., *115*:452, 1976.
28. Sohval, A. R.: Testicular dysgenesis as an etiologic factor in cryptorchidism. J. Urol., *72*:693, 1954.
29. Wangenstein, O. H.: Undescended testes: Experimental and clinical study. Arch. Surg., *14*:653, 1927.
30. Weiss, R. M., Glickman, M. G., and Lytton, B.: Clinical implications of gonadal venography in the management of the non-palpable undescended testis. J. Urol., *121*:745, 1979.

456 North New Ballas Road
St. Louis, Missouri 63141