

# Ovary cryopreservation and transplantation for fertility preservation

S.J. Silber\*

Infertility Center of St. Louis, St. Luke's Hospital, 224 South Woods Mill Road, St. Louis, MO 63017, USA

\*Correspondence address. E-mail: [silber@infertile.com](mailto:silber@infertile.com)

Submitted on November 14, 2011; resubmitted on November 14, 2011; accepted on December 19, 2011

**ABSTRACT:** The aim of this review is to summarize the state-of-the-art of ovarian transplantation and cryopreservation. This field has progressed over the last half century from simple animal experiments to sophisticated application in humans. The initial poor results in humans began to improve when a series of nine monozygotic (MZ) twin pairs discordant for premature ovarian failure (POF) underwent ovary transplantation at one center. All of these fresh ovary transplants were successful, resulting in 11 healthy babies in 7 of the 9 recipients. The same surgical techniques were then applied to 3 frozen ovary tissue transplants, up to 14 years after the ovary had been frozen, resulting in 3 more healthy babies. Around the world, the number of healthy babies has now risen to 28. Even ovary allotransplantation is being attempted in the not so uncommon situation where a previous bone marrow donor is now willing to donate ovarian tissue to the same recipient. Recipients routinely reinitiated ovulatory menstrual cycles and normal Day 3 serum FSH levels by 4.5 months. Most conceived naturally (three of them twice or three times from the same graft). The duration of function of fresh ovarian grafts, contrary to initial expectations, indicated minimal oocyte loss from ischemia time. Grafts of just modest portions of ovarian tissue have lasted >7 years. *In vitro* studies suggest that vitrification of ovarian tissue may be an improvement over the 70% oocyte viability loss from slow freeze.

**Key words:** ovary transplantation / cryopreservation / fertility preservation / vitrification ovary tissue / cancer and infertility

## Introduction

The first successful fresh human ovary transplantation was reported between a pair of remarkable monozygotic (MZ) twins discordant for premature ovarian failure (POF) using a cortical grafting technique (Silber *et al.*, 2005). The first successful human frozen ovary auto-grafts were reported around the same time with tissue cryopreserved for cancer patients prior to their sterilizing bone marrow transplants (Donnez *et al.*, 2004; Meirou *et al.*, 2005). This followed similar results described in the sheep over a decade earlier (Gosden *et al.*, 1994). The technique has subsequently been refined over a larger series of nine consecutive successful fresh ovary transplants in identical twins discordant for POF, plus two fresh allotransplants, with a resumption of normal hormonal cycling and menstruation in all cases, eventually leading to 14 pregnancies and 11 healthy babies born from the 9 fresh identical twin recipients (Silber and Gosden, 2007; Silber *et al.*, 2008a, b; Silber *et al.*, 2010). This unusual consecutive series of fresh ovary cortical transplants helped us also refine the techniques necessary for successful preservation of fertility for cancer patients using an ovarian tissue freezing technique, with three additional successful pregnancies from three frozen transplants. This unusual series also helped us to establish a method for distinguishing

between the egg loss from transplant ischemia time versus the egg loss from cryopreservation. We now can report long-term follow-ups (up to 8 years) of this original series, and add to it our more recent experience with cryopreserved ovarian tissue. The results appear to be remarkably more robust than had originally been contemplated.

## Fresh series of identical twins with POF

Ten MZ twin pairs aged 24–40 years presented with discordant ovarian function, one sibling normal and the other having POF. Nine of the 10 elected to undergo transplantation of an ovary from the normal twin to the twin with POF. Eight of the nine had a cortical graft transplant and one had an intact whole ovary transplant. POF was diagnosed after >4 years of amenorrhea accompanied by elevated serum levels of gonadotrophins, >50 mIU/ml. Their sisters, in contrast, still had normal menstrual cyclicity, normal gonadotropin levels, and eight of the nine donors had successful pregnancy histories. The twins inquired about this possibility originally from researching an earlier testis transplant we had reported for anorchia (Silber, 1978; Silber *et al.*, 2005; Bedaiwy and Falcone, 2007). The patients volunteered many reasons for preferring transplantation over conventional

oocyte donation. Many of them had previous failures with donor oocyte IVF cycles, and did not want to go through more IVF. Some had the opportunity to donate an ovary at the same time as having a surgery they required for other gynecologic problems (such as fibroids or cysts). All of them found the possibility of natural conception more attractive than IVF and egg donation. In most cases, the twins lived far apart (even in different countries) and the donors preferred to make a single visit for a one-time ovary donation, rather than go through multiple cycles of ovarian hyperstimulation.

All studies were carried out with informed consent under protocols approved by the Institutional Review Board and the Ethics Committee of St. Luke's Hospital (St. Louis, MO, USA). Despite risks, the evidence does not support a deleterious effect of unilateral oophorectomy either on fertility or on age of menopause (Gosden *et al.*, 1989; Faddy *et al.*, 1992).

One entire ovary of the donor was removed and the cortex dissected away from the medulla. The cortex of the non-functioning recipient ovaries was removed in entirety, and the donor cortex slices were transplanted onto the exposed medulla using 9-0 nylon interrupted sutures. A tiny piece of spare tissue of the donor, as well as the entire resected atrophied ovarian cortex of the recipient was examined histologically in all cases (Fig. 1A and B). It should be noted that we avoided micro-hematoma formation under the graft by micro-bipolar cautery and micro-pressure stitches. Constant pulsatile irrigation with heparinized saline prevented adhesions (Fig. 2A–D). Only one-third of the ovarian cortex was grafted fresh and two-thirds were frozen.

## Ovarian cryopreservation by original slow freeze technique

All of our fresh clinical transplant studies involved cryopreservation of spare tissue for future thawed transplants. All of the frozen cases thus far transplanted have utilized the slow freeze approach (Gook *et al.*, 1999). For slow freezing, after enucleating medullary tissue with a sharp scalpel dissection, the cortex was pared down manually to an ultrathin translucent shell with a thickness of  $\leq 1$  mm. Tissue for cryopreservation was divided into multiple strips and transferred to 1.5 ml cryovials after equilibration in 1.5 mol/l 1,2-propanediol and 0.1 mol/l

sucrose at 37°C for 30 min, followed by 1.5 mol/l 1,2-propanediol and 0.2 mol/l sucrose for 5 min, then cooled at a controlled rate, as described previously (Gosden *et al.*, 1994). Thawing was achieved rapidly by agitating the vials in a warmed water bath. If tissue had thickened by contraction after thawing, it was pared down again to  $< 1$  mm under an operating microscope with microsurgical scissors before transplantation (Newton *et al.*, 1996).

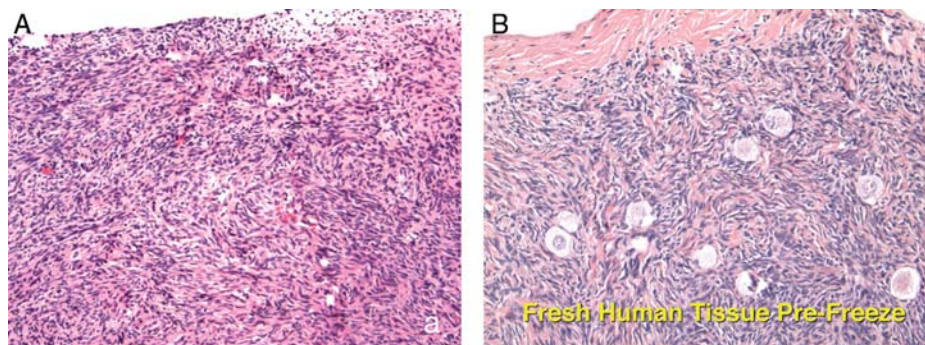
However, we now use vitrification exclusively for cryopreservation in humans because of our *in vitro* viability analysis studies as well as *in vivo* transplant studies in the bovine (Kagawa *et al.*, 2009). A total of 16 cancer patients requesting fertility preservation by ovarian banking consented to an oocyte viability test and histologic review of a small sample ( $< 10\%$ ) of their fresh or preserved tissue. In eight cases, the tissue had been preserved by vitrification, six by a slow freezing protocol and in two only fresh tissue was analyzed. The goal of this *in vitro* study was to determine which method produced a higher cell survival rate (Silber *et al.*, 2010).

The high viability (92%) of oocytes in both control (fresh) specimens and vitrified specimens indicated that disaggregation *per se* had only caused minimal damage to this cell type (Silber *et al.*, 2010). Overall, 2301 oocytes were examined from 16 specimens. The results within each of the three groups revealed no significant difference overall between fresh and vitrified tissue, but the viability of slow freeze-cryopreserved tissue was less than one-half (42%;  $P < 0.01$ ). Transmission electron microscopy also has been used to analyze ovarian tissue that had been either cryopreserved by slow freezing or vitrified by ultrarapid freezing, showing vitrification to be superior (Keros *et al.*, 2009).

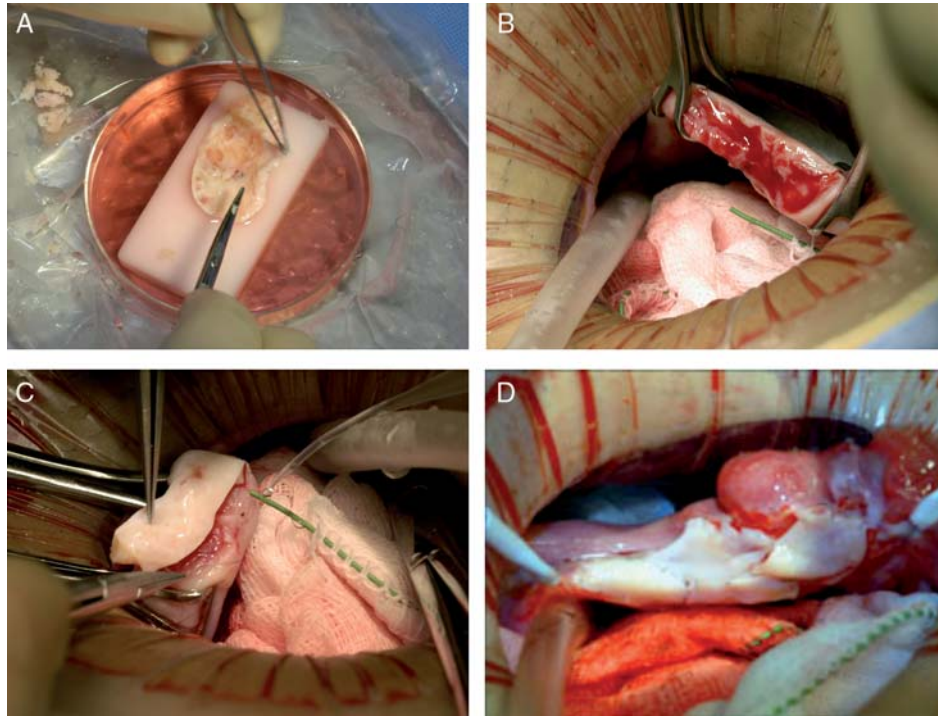
It will be some time before we can accumulate the same clinical experience with transplantation of our vitrified samples as it required 15 years to gain experience with slow freeze samples (it takes that long for many of these patients to come back for their frozen transplant). However, the *in vitro* evidence strongly favors vitrification.

## Ovarian tissue vitrification technique

Cortex tissue of each ovary is cut into slices of  $1 \times 10 \times 10$  mm. The precise 1-mm tissue thickness was guaranteed with a tissue



**Figure 1** (A) Showing the absence of primordial or pre-antral follicles in ovarian biopsies of this candidate for ovarian transplantation compared with (B) that in her fertile sister. Republished from Silber *et al.* (2008a, b) with permission.



**Figure 2** Steps in the procedure of ovarian transplantation between MZ twin sisters: **(A)** preparation of donor ovarian cortex by dissection in a Petri dish on ice; **(B)** preparation of recipient ovarian medulla; **(C)** attaching donor cortical tissue to recipient ovarian medulla; **(D)** attaching thawed donor cortical tissue for re-transplantation to the recipient medulla. Republished from Silber *et al.* (2008a, b) with permission.

slicer designed explicitly for this purpose (Kitazato Biopharma, Japan). The tissue slicer is put on the surface of ovary. Then another plate is placed over the tissue slicer, and the ovary is cut between the slicer and the surface of the ovary using a sharp blade. The cortical ovarian tissue is thus cut into  $1 \times 10 \times 10$  mm pieces. The ultra-thinness of the tissue is crucial, not only for the cryopreservation, but also for rapid revascularization after grafting.

Ovarian tissues are initially equilibrated in 7.5% ethylene glycol (EG) and 7.5% dimethyl sulphoxide (DMSO) in handling medium (HM: HEPES-buffered TCM-199 solution supplemented with 20% (v/v) synthetic serum substitute (SSS; Irvine Scientific, Santa Ana, CA, USA) for 25 min followed by a second equilibration in 20% EG and 20% DMSO with 0.5 mol/l sucrose for 15 min. Ovarian tissues are then placed in a minimum volume of solution (virtually 'dry') onto a thin metal strip (Cryotissue: Kitazato BioPharma, Fujinomiya, Japan), and submerged directly into sterile liquid nitrogen (Fuentes and Dubettier, 2004), following which the strip was inserted into a protective container and placed into a liquid nitrogen storage tank.

For thawing, the protective cover is removed and the Cryotissue metal strip is immersed directly into 40 ml of 37°C HM solution supplemented with 1.0 mol/l sucrose for 1 min. Then, the ovary tissues are transferred into 15 ml of 0.5 mol/l sucrose HM solution for 5 min at room temperature, and washed twice in HM solution for 10 min before viability analysis, or transplantation. No ice crystal formation occurs during any of these vitrification procedures (Kagawa *et al.*, 2009).

## Cortical ovarian tissue transplantation technique

For fresh ovary transplants, under general anesthesia, one ovary is removed from the donor using laparoscopy or minilaparotomy. The whole ovary is transferred to a Petri dish for dissection by hand with a scalpel and toothed forceps. It was felt important to prepare a cortical tissue slice no thicker than  $\approx 1.5$  mm to facilitate rapid revascularization while keeping the tissue constantly irrigated with ice-cold Leibovitz L-15 medium (Fig. 2A). We now recommend a special Kitazato tissue slicer rather than dissecting by hand, in order to get a thinner slice. But for these initial fresh cases, the hand pared cortex was divided into several pieces of approximately equal size for grafting, one piece to each recipient ovary. The remaining two-thirds of the cortical tissue was cryopreserved (Newton *et al.*, 1996; Gook *et al.*, 1999; Oktay *et al.*, 2004; Rosendahl *et al.*, 2006). The technique for transplanting thawed ovarian cortical tissue is no different from fresh cortical tissue.

The recipients were prepared by minilaparotomy via a 3.5-cm incision above the pubis. For cortical tissue transplantation, recipient ovarian cortex was resected to completely expose medullary tissue (Fig. 2B); hemostasis was controlled with micro-bipolar forceps, and irrigation with heparinized saline was performed to avoid adhesion formation or micro-hematomas between donor and recipient tissues. This technique may be the most important reason for a minimal ischemic loss of oocyte viability. The tissue graft was trimmed to the dimensions of the exposed surface of the recipient and attached using 9-0



interrupted sutures under an operating microscope (Fig. 2C). Very importantly, the medullar bed was also sutured to the under surface of the cortical graft with 9-0 sutures to maintain tight tissue approximation, again to avoid micro-hematoma formation under the cortical grafts (Fig. 2D). After removing the old cortex to accommodate the new one, all discarded tissue was examined histologically and found to be completely devoid of follicles. All patients were released from the hospital the same day or the following morning, and had a rapid and uneventful recovery. In the one case of bilateral absence of ovary and ampulla, the graft was attached to the fallopian tube isthmus rather than the ovarian medulla.

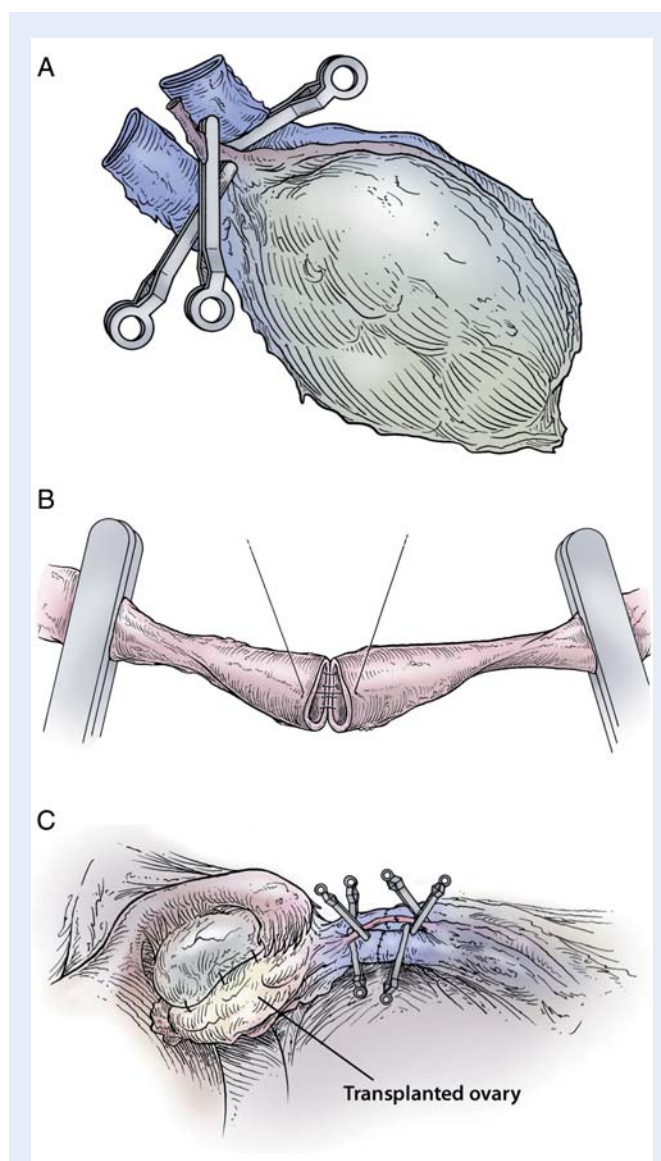
## Intact whole ovary transplantation

To transplant an intact whole ovary, the donor ovary is removed by clamping the infundibular pelvic ligament at its base in order to obtain a maximum length. The veins (3–5 mm) are easily identified, but the ovarian artery (0.3 mm) is often not grossly visible. The entire specimen is placed in the Leibovitz medium at 4°C and two veins and one artery were dissected and isolated under the operating microscope. The recipient's infundibular pelvic ligament is clamped at the base and transected close to her non-functioning ovary. The donor's ovarian veins are then anastomosed to the recipient's with 9-0 nylon interrupted sutures, and the ovarian arteries are anastomosed with 10-0 nylon interrupted sutures (Fig. 3A–C). When the micro-vascular clamps are removed, blood flow is confirmed by fresh bleeding from the surface of the ovary where a cortical slice had been taken for cryopreservation as a backup. The original concept behind whole intact ovary micro-vascular transplantation was to avoid the supposed damage that was incorrectly attributed to cortical grafting (Baird *et al.*, 1999). Current results seem to eliminate the need for whole ovary transplantation, as these fresh cortical ovarian tissue grafts have now been shown to have a long duration of function.

## Results of fresh and frozen ovarian transplantation

Results are summarized in Table 1 and in Figs 4 and 5. All nine identical twin pairs underwent their orthotopic ovarian is transplantation between April 2004 and April 2008. The recipients, for the most part, continued to cycle from 2 years in two patients whose donor had low ovarian reserve to over 6 or 7 years in most cases. The two patients whose donor had low antral follicle counts (AFC) of <10, only functioned for 2 years. However, even these two cases had spare frozen cortical tissue that remains available for future transplants. Menstrual cycles began within 3 months and Day 3 FSH levels returned to normal by 4.5 months in all cases (Figs 4 and 5). A total of 14 healthy babies resulted from the 12 ovary transplants, 11 from the 9 fresh transplants and 3 from the three frozen transplants (Table 1).

One of our twins became pregnant at 39 years of age (note that the donor sister of course was also 39 years old) without medical assistance after her fifth menses, 8 months after transplantation. She delivered a healthy baby girl at full term and then conceived again at age 42, and delivered a healthy baby boy, again at full term, 4 years after her transplant. Her ovary is still functioning to date after 7 years, and she



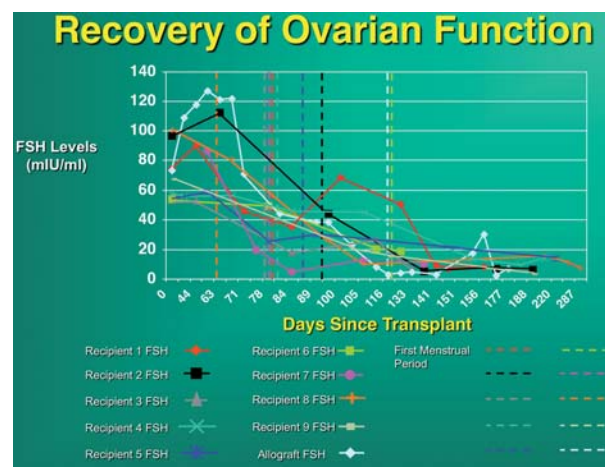
**Figure 3** Steps in the procedure of intact ovary microvascular transplantation: (A) micro-surgical isolation of donor ovary blood supply; (B) end-to-end anastomosis of ovarian blood vessel; (C) completed anastomosis of ovarian artery and veins. Republished from Silber *et al.* (2008a, b) with permission.

conceived again at age 45 with another healthy boy, >7 years after her transplant. One case of ovary transplant was an identical twin whose POF was caused by a bone marrow transplant with pelvic irradiation for leukemia, with her identical twin sister being the donor. She became spontaneously pregnant 5 months after her fresh ovary transplant from her sister, but miscarried. Then at 1.5 years she became pregnant again and had a healthy baby, and at 5 years after the transplant, she became pregnant again, and had a second healthy baby. Over 6 years later, her original transplant is still functioning, and she still has two-thirds of an ovary that remains frozen. It does not appear from this or from the frozen cases that pelvic radiation is incompatible with a healthy pregnancy, and in fact, it appears (contrary to expectations) that transplantation of ovarian cortical tissue using this technique is a very robust procedure.

**Table 1** Ovarian transplant results (14 babies: 11 from 9 fresh and 3 from 3 frozen).

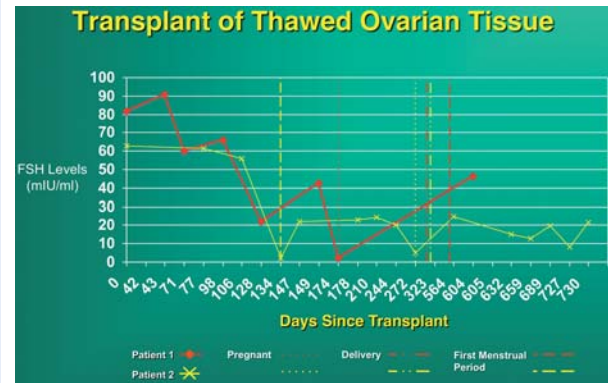
Pt #	Age	Pre-OP FSH	Post-OP FSH	Initial Post-OP menses intervals	Preg	Babies delivered	Years of graft function
1	24	75	7.1	2nd baby:FROZEN	3	2	4
2	38	96	5.2	93, 42, 24, 27, 25...	3	3	>7
3	25	112	6.8	76, 23, 30, 26, 25, 26, 21, 24, 27, 34, 25, 27, 51, 30, 27, 26, 28, 19...	1	2	>6
4	34	58	9.4	81, 22, 47, 26, 21, 20, 27, 26...	2	1	4
5	40	60	6.8	86, 29, 38, 34, 28, 28, 31, 35, 34, 28, 33, 35, 30...	0	0	4
6	26	101	7.5	64, 20, 39, 40, 32, 26, 29, 26, 26, 41...	1	1	2
7	34	86	4.4	83, 22, 29, 29...	3	2	>6
8	37	86	7.4	100, 17, 39, 29, 27, 22, 23, 20, 34, 25, 26, 29...	1	1	>4
9	35	54	4.2	128, 42, 18, 25...	1	0	2
10	31	78	3.4	Frozen	1	1	2
11	33	85	8.6	Frozen	1	1	>1

\*Note: each graft represents only one-third of one ovary or one-sixth of entire ovarian reserve.



**Figure 4** Recovery of ovarian function. The eight fresh transplant cases showed a dramatic decline in Day 3 serum FSH by 80–140 days post-operatively corresponding approximately to the resumption of menses. The results of the micro-vascular whole ovary transplant and the cortical tissue allotransplant are not significantly different from cortical isografts.

Only one patient failed to conceive, but she had a marginal AFC and was 41 years old at the time of the transplant. However, the ovary continued to function despite her age and low ovarian reserve (and the age of her donor) for over 4 years, and she still has two-thirds of the ovary frozen for future transplantation. One case had a micro-vascular whole intact ovary transplant and is continuing to cycle regularly. She became pregnant and delivered a healthy baby 2 years later. But it does not appear that her more difficult procedure (micro-vascular whole ovary transplantation) was necessary, as she would have done just as well with a simple outpatient cortical graft.



**Figure 5** Transplantation of thawed ovarian tissue. After a frozen cortical re-transplant, serum FSH declined again to normal levels, similar to those of fresh transplants.

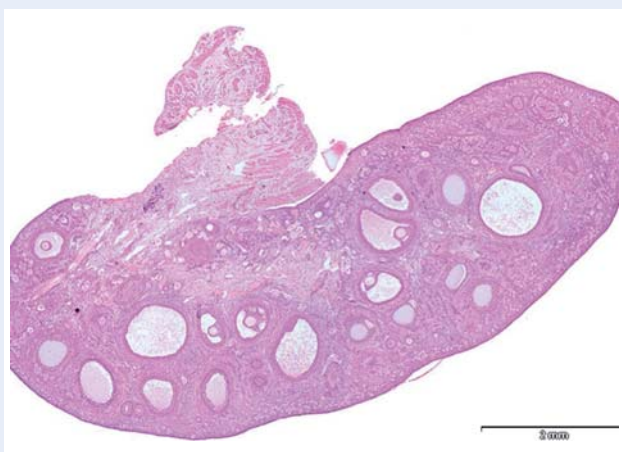
This newly favorable experience with ovarian cortex grafting is not limited just to our center (Donnez et al., 2011). Equally robust results are being experienced in Brussels, Paris, Spain, Denmark and Israel. Frozen ovarian grafts (even with the slow freeze technique) in Denmark are lasting over 5 years and many spontaneous pregnancies have been reported with no need for IVF or other ancillary treatment. At the time of this writing, 28 healthy babies have been born from ovarian tissue grafting, and most involved no IVF, and resulted from just regular intercourse with no special treatment (see Table II).

### Frozen cortical ovarian transplantation

The most common benefit of ovarian transplant is not these unusual cases of fresh grafting but rather to protect the fertility and future endocrine function of young women undergoing cancer treatment

**Table II Worldwide frozen ovarian cortical tissue transplantation pregnancies.**

Case #	Diagnosis	Babies	Study
1	Hodgkins	1	Donnez
2	Neurotumor	1	Donnez
3	Non-Hodgkins	1	Meirow
4	Hodgkins	1	Demeestere
5	Ewings	3	Andersen
6	Hodgkins	1	Andersen
7	POF	1	Silber
8	Hodgkins	2	Silber
9	Polyangiitis	1	Piver
10	Breast cancer	2	Pellicer
11	Sickle cell	1	Piver
12	Hodgkins	2	Revel
Totals: 12 patients		17 babies	8 centers
Fresh + frozen		28 babies	Silber: 14 babies



**Figure 6** All the primordial follicles of the ovary are located in the outer layer of 0.75 mm of the cortex. Therefore, very thin slices of cortex will contain all these follicles and allow rapid revascularization.

(Bleyer, 1990; Ries, 1999; Larsen *et al.*, 2003; Anderson *et al.*, 2006; Lee *et al.*, 2006; Anderson and Cameron, 2007; Jeruss and Woodruff, 2009; Kagawa *et al.*, 2009; Silber *et al.*, 2010). Since 1996, we have frozen ovary tissue for 62 young women with solid organ cancer, or with a great risk for POF, of whom 16 had spare frozen tissue subjected to detailed viability testing before cryopreservation and after thawing. All 62 had histologic review by a variety of pathologists. Only one had ovarian metastasis, a young woman with widespread breast cancer metastasis throughout her entire body. Otherwise, none of our other 61 cases had any tumor cells in their ovary. Andersen has also noted a complete lack of ovarian metastasis, even in the majority of leukemia cases (Fig. 6). The reason for the remarkable absence of ovarian metastasis might possibly be due to the fibrous avascular nature of the ovarian cortex (Professor Claus Andersen,

personal communication). In fact, the reason why fetal ovarian tubules (which in the fetal male become seminiferous tubules) invade the fibrous cortex and become follicles, is that the dense fibrous tissue of the cortex (which in the fetal and adult testis is just tunica albuginea) is needed to suppress the resting follicles from developing all at once prematurely.

With the classical slow freeze technique, our *in vitro* viability testing showed only 41% of oocytes survived (Newton *et al.*, 1996; Gook *et al.*, 1999; Kagawa *et al.*, 2009; Silber *et al.*, 2010). However, with vitrification of the ovarian tissue there was no difference between fresh unfrozen controls and frozen tissue. It seems likely, therefore, that vitrified ovarian tissue would give better results after transplantation than tissue cryopreserved by slow freeze, but it is too early to state that with any certainty.

Thus far, only three of our patients have had their frozen tissue transplanted back. In all three cases, the tissue was cryopreserved with slow freeze because this was before we adopted vitrification as our standard method in 2009. In addition to these 62 pathologic cases, 7 women have had ovarian tissue frozen simply to allow them the possibility of having children at an older age because they had to delay childbearing for strong personal and economic reasons. All of these women are more recent cases, and had their ovarian tissue frozen with vitrification (Kagawa *et al.*, 2009; Silber *et al.*, 2010).

Of our three cases of frozen transplanted tissue thus far, even with slow freeze, all have had a robust return of ovulatory menstrual cycles within 4 months with spontaneous pregnancy eventually. In general, recipients of thawed ovarian cortical autografts had the same pattern of return of function as we saw with fresh grafts (Fig. 5). However, the duration of function for these slow freeze grafts was less than 2 years, about one-third or less than that of our fresh grafts. This could be an intrinsic problem with slow freeze, or a problem with our slow freeze technique. We hope that with vitrification, because we found no loss of oocyte viability, that the frozen grafts will last as long as the fresh ones. It is clear from our fresh grafts that with a proper micro-surgical technique, ischemia time is not a problem for cortical grafting. The only issue remaining is what is the optimal method of cryopreservation?

## Genetics of non-cancer POF, and low ovarian reserve

None of the medical histories provided an explanation for POF with a follicular ovaries in the recipients, except for one who had received chemotherapy, and bone marrow transplant for leukemia. The clinical histories of POF in the other nine MZ cases were idiopathic and consistent with a congenital deficiency of germ cells. According to a mathematical model (Faddy *et al.*, 1992), the follicle reserve at birth must be very small to account for POF as early as adolescence or young adulthood.

Identical twins discordant for ovarian function present a true genetic puzzle. The great majority of women enter menopause in their fifth or sixth decade of life, at an average of 51 years, but 1% undergo menopause quite prematurely, i.e. before 40 years of age (Coulam *et al.*, 1986; Riboli *et al.*, 2002; Luborsky *et al.*, 2003). POF frequently has a genetic etiology and menopausal age normally is strongly heritable judging by the greater concordance between MZ than dizygotic



twins (Snieder *et al.*, 1998; De Bruin *et al.*, 2001; Van Asselt *et al.*, 2004; Goswami and Conway, 2005). It was remarkable to identify MZ twin pairs in which one sister had undergone menopause for unexplained reasons at a very early age from 14 to 22 years, whereas the other, was still fertile with naturally conceived children, as well as normal ovulatory cycles and ovarian reserve (Silber *et al.*, 2005; Silber and Gosden, 2007; Silber *et al.*, 2008a, b). We have not yet taken advantage of the unique opportunity these twins offered for studying the genetic origin of ovarian reserve, but genomic DNA and lymphoblastoid cell lines were prepared and carefully stored for future genetic and epigenetic studies. Details of the obstetric records on the original chorionicity at birth of these identical twin sisters revealed that 50% were monozygotic-monoamniotic, which was surprisingly high since the incidence of mono/mono is normally only  $\approx 2\%$  ( $P < 0.0005$ ). It is clear that late splitting, for whatever reason, predisposes otherwise identical twins to discordant germ cell deficiency (Su, 2002; Gosden, *et al.*, 2007; Silber *et al.*, 2008a).

Thus far the search for genes controlling ovarian reserve in the human has yielded meager results, the only modestly common candidate being the pre-mutation carrier status for fragile X. The answer oddly enough may be found in the structural peculiarity of the Y chromosome, with its huge concentration of amplicons and palindromes, which are very difficult to sequence (Silber, 2011). These regions of long sequence identity with many multi-copy genes have been completely missed on the X chromosome that did not undergo the very specialized type of sequencing used for the Y, and these are the types of sequence that may likely harbor gametogenesis genes. We now estimate that 12% of the X chromosome remains unsequenced, and in fact is ampliconic, making the X chromosome a very attractive place to find genes which control ovarian reserve. But to sequence these ampliconic regions is a very slow and laborious task.

## Future prospects

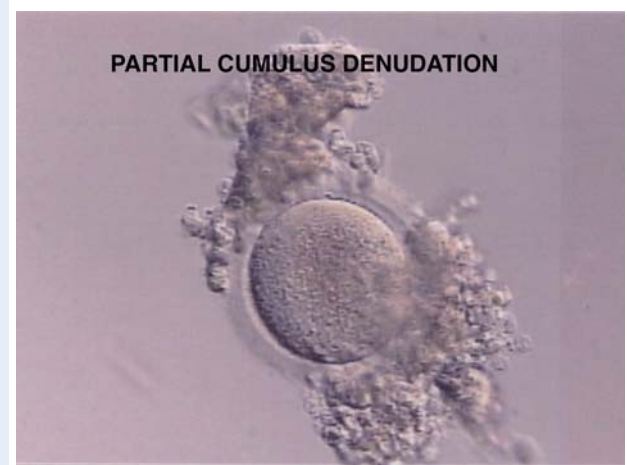Conventional oocyte donation is the common treatment for patients with POF who want to become pregnant. Nevertheless, the robust results obtained in every case of this series of isogenetic twins give confidence in ovarian transplantation as an alternative strategy for overcoming sterility. Furthermore, it appears that cryopreservation and subsequent transplantation of ovarian tissue is more robust than had been thought in the previous decade. Although the surgery might seem more burdensome than oocyte retrieval, it is a straightforward and uneventful outpatient procedure, which has been effective in all our cases thus far in restoring menstrual cycles and long-term ovarian function and enabling establishment of viable pregnancies in the majority of cases. After ovarian transplantation, the patients were able to attempt natural conception every month without medical assistance. Heterotopic sites have produced no successful pregnancies to date and our patients preferred the chance of natural conception (Hilders *et al.*, 2004; Kim *et al.*, 2004; Oktay *et al.*, 2004; Rosendahl *et al.*, 2006). It would appear that there is little oocyte loss from the grafting technique (contrary to popular assumptions) and no obvious loss from cryopreservation with vitrification. In fact, the commonly held view that egg freezing is a proven technique and ovary tissue transplantation is 'experimental,' is belied by the fact that all of the successful pregnancies resulting from fertility

preservation in cancer patients have been from frozen ovary tissue, and none to date have come from frozen oocytes (Donnez *et al.*, 2011).

It is generally assumed that POF or low ovarian reserve is related to the number of primordial follicles the woman has at birth and this number is certainly heritable and is most likely genetically determined (Gosden *et al.*, 2007). All modern women are concerned about what is commonly referred to as their 'biological clock' as they worry about the chances of conceiving by the time they have established their career and/or their marriage and their financial stability. Most of our cured cancer patients, who have young ovarian tissue frozen, feel almost grateful they had cancer, because otherwise they would share this same fear all modern, liberated women have about their 'biological clock.' But it is not only having a child that worries them.

In Denmark, demographers are predicting that 25% of women today will live to age 100. They will not want to be menopausal women for half of their lifetime. Aside from freezing eggs for these 'social' reasons, which more and more young women are doing, freezing ovarian tissue could preserve not only their chance for having a child, but could also prevent them from ever having to go through menopause.

For leukemia patients, or any patients in whom transplantation of prior frozen ovarian tissue might create a risk of re-introducing cancer cells, we recommend that before the cortical tissue is dissected and frozen, that all the antral follicles of the removed ovary be aspirated for germinal vesicle oocyte (GV) retrieval. These GV's can then be partially denuded of cumulus cells, and vitrified just as for oocyte freezing (with a few minor modifications; see Fig. 7). The reasons for partially denuding these GV's (which can be retrieved in large numbers with no hormonal stimulation) are twofold: (i) to allow ready penetration into the oocyte of the cryoprotectant media and (ii) to preserve enough cumulus cells to allow for later *in vitro* maturation of the GV oocyte. Thus, even patients with blood borne cancers may possibly have safe preservation of future fertility. However, it is possible that most leukemia patients will not have metastasis to the ovarian cortex as previously feared, and may very



**Figure 7** Partial cumulus denudation prior to vitrification of GV oocytes.

well eventually be able also to have a cortical transplant (Professor Claus Andersen, personal communication).

The major application of ovarian tissue cryopreservation and transplantation is obviously for fertility preservation in cancer patients and possibly for women who need to delay childbearing. However, for patients who have already lost ovarian function from bone marrow transplant, allografts may be an option. Allografts might be considered if ovarian tissue is available from a young woman who previously donated bone marrow to the same patient. However, it is very important not to attempt this without immune suppression if the graft recipient has any sign of graft versus host. Reassuringly, well-matched (human leukocyte antigen) kidney transplant recipients on immunosuppression have favorable obstetric outcomes (Armenti *et al.*, 2000).

At the time of this writing, we are aware of numerous other births after implanting ovarian tissue for a total of 28 live births thus far (Donnez *et al.*, 2004; Meirou *et al.*, 2005; Demeestere *et al.*, 2007; Andersen *et al.*, 2008; Piver *et al.*, 2009; Sanchez-Serrano *et al.*, 2010; Donnez *et al.*, 2011). Thus, despite initial skepticism, this technique is now gaining worldwide acceptance, and is being enthusiastically received by young women of reproductive age with cancer. Furthermore, it might become a preferred method for preservation of fertility for 'social' reasons, and could completely eliminate the prospect of menopause.

## Conclusions

The evidence from this series for the effectiveness of both fresh and frozen ovary tissue transplants gives support for the position that cryopreservation of ovarian tissue for cancer patients should no longer be considered experimental, and might even be ready for consideration by women without cancer who must delay childbearing for other reasons.

## Acknowledgements

The author would like to thank Professor Roger Gosden for his inspiration from the very beginning, and Masahige Kuwayama and Nori Kagawa for taking cryopreservation to a completely new level of perfection. He would also like to thank Sharon Fuller for preparation of the manuscript. I wish to dedicate this manuscript to Professor Roger Gosden, my inspiration during all this work, my mentor and my dear friend.

## References

- Anderson RA, Cameron DA. Assessment of the effect of chemotherapy on ovarian function in women with breast cancer. *J Clin Oncol* 2007; **25**:1630–1631. Author reply 1632.
- Anderson RA, Themmen AP, Al-Qahtani A, Groome NP, Cameron DA. The effects of chemotherapy and long-term gonadotrophin suppression on the ovarian reserve in premenopausal women with breast cancer. *Hum Reprod* 2006; **21**:2583–2592.
- Andersen CY, Rosendahl M, Byskov AG, Loft A, Ottosen C, Dueholm M, Schmidt KLT, Andersen AN, Ernst E. Two successful pregnancies following autotransplantation of frozen/thawed ovarian tissue. *Hum Reprod* 2008; **23**:2266–2272.
- Armenti VT, Radomski JS, Moritz MJ, Philips LZ, McGrory CH, Coscia LA. Report from the National Transplantation Pregnancy Registry (NTPR):

- outcomes of pregnancy after transplantation. *Clin Transplants* 2000; **5**:123–134.
- Baird DT, Webb R, Campbell BK, Harkness LM, Gosden RG. Long-term ovarian function in she; after ovariectomy and transplantation of autografts stored at  $-196^{\circ}\text{C}$ . *Endocrinology* 1999; **140**:462–471.
- Bedaiwy MA, Falcone T. Harvesting and autotransplantation of vascularized ovarian grafts: approaches and techniques. *Reprod Biomed Online* 2007; **14**:360–371.
- Bleyer WA. The impact of childhood cancer on the United State and the world. *CA Cancer* 1990; **40**:355–367.
- Coulam CB, Adamson SC, Annegers JF. Incidence of premature ovarian failure. *Ob/Gyn* 1986; **67**:604–606.
- De Bruin JP, Bovenhuis H, van Noord PA, Pearson P, van Arendonk JA, te Velde ER, Kuuran VVW, Dorland M. The role of genetic factors in age at natural menopause. *Hum Reprod* 2001; **16**:2014–2018.
- Demeestere I, Simon P, Emiliani S, Delbaere A, Englert Y. Fertility preservation: successful transplantation of cryopreserved ovarian tissue in a young patient previously treated for Hodgkin's disease. *Oncologist* 2007; **12**:1437–1442.
- Donnez J, Dolmans MM, Demylle D, Jadoul P, Pirard C, Squifflet J, Martinez-Madrid B, Van Langendonck A. Livebirth after orthotopic transplantation of cryopreserved ovarian tissue. *Lancet* 2004; **364**:1405–1410.
- Donnez J, Martinez-Madrid B, Jadoul P, Van Langendonck A, Demylle D, Dolmans MM. Ovarian tissue cryopreservation and transplantation: a review. *Hum Reprod Update* 2006; **12**:519–535.
- Donnez J, Silber S, Andersen CY, Demeestere I, Piver P, Meirou D, Pellicer A, Dolmans M. Children born after autotransplantation of cryopreserved ovarian tissue. A review of 13 live births. *Ann Med* 2011; **43**:437–450.
- Faddy MJ, Gosden RG, Gougeon A, Richardson SJ, Nelson JF. Accelerated disappearance of ovarian follicles in mid-life: implications for forecasting menopause. *Hum Reprod* 1992; **7**:1342–1346.
- Fuentes F, Dubettier R. *Air Separation Method and Plant, United States Patent*. Patent No. US 6,776,005 B2, 2004.
- Gook DA, Edgar DH, Stern C. Effect of cooling rate and dehydration regimen on the histological appearance of human ovarian cortex following cryopreservation in 1,2-propanediol. *Hum Reprod* 1999; **14**:2061–2068.
- Gosden RG, Telfer E, Faddy MF, Brook DJ. Ovarian cyclicity and follicular recruitment in unilaterally ovariectomized mice. *J Reprod Fert* 1989; **87**:257–264.
- Gosden RG, Baird DT, Wade JC, Webb R. Restoration of fertility to oophorectomized sheep by ovarian autografts stored at  $-196$  degrees C. *Hum Reprod* 1994; **9**:597–603.
- Gosden RG, Treloar SA, Martin NG, Cherkas LF, Spector TD, Faddy MJ, Faddy MJ, Silber SJ. Prevalence of premature ovarian failure in monozygotic and dizygotic twins. *Hum Reprod* 2007; **22**:610–615.
- Goswami D, Conway GS. Premature ovarian failure. *Hum Reprod Update* 2005; **11**:391–410.
- Gougeon A. Dynamics of follicular growth in the human: a model from preliminary results. *Hum Reprod* 1986; **1**:81–87.
- Hilders CG, Baranski AG, Peters L, Ramkhelawan A, Trimbos JB. Successful human ovarian autotransplantation to the upper arm. *Cancer* 2004; **101**:2771–2778.
- Jeruss JS, Woodruff TK. Preservation of fertility in patients with cancer. *N Engl J Med* 2009; **360**:902–911.
- Kagawa N, Silber S, Kuwayama M. Successful vitrification of bovine and human ovarian tissue. *Reprod Biomed Online* 2009; **18**:568–577.
- Keros V, Xella S, Hultenby K, Petterson K, Sheiklin M, Volpe A *et al.* Vitrification versus controlled rate freezing in cryopreservation of human ovarian tissue. *Hum Reprod* 2009; **24**:1670–1683.



- Kim SS, Hwang IT, Lee HC. Heterotopic autotransplantation of cryobanked human ovarian tissue as a strategy to restore ovarian function. *Fertil Steril* 2004;**82**:930–932.
- Larsen EC, Muller J, Schmiegelow K, Reznitzer C, Andersen AN. Reduced ovarian function in long-term survivors of radiation and chemotherapy-treated childhood cancer. *J Clin Endocrinol Metab* 2003;**88**:5307–5314.
- Lee SJ, Schover LR, Partridge AH, Patrizio P, Wallace WH, Hagerty K, Beck LN, Brennan LV, Oktay K. American Society of Clinical Oncology. American Society of Clinical Oncology recommendations on fertility preservation in cancer patients. *J Clin Oncol* 2006;**24**:217–2931.
- Luborsky JL, Meyer P, Sowers MF, Gold EB, Santoro N. Premature menopause in a multi-ethnic population study of the menopause transition. *Hum Reprod* 2003;**18**:199–206.
- Meirow D, Levron J, Eldar-Geva T, Hardan I, Fridman E, Zalel Y et al. Pregnancy after transplantation of cryopreserved ovarian tissue in a patient with ovarian failure after chemotherapy. *N Engl J Med* 2005;**353**:318–321.
- Newton H, Aubard Y, Rutherford A, Sharma V, Gosden R. Low temperature storage and grafting of human ovarian tissue. *Hum Reprod* 1996;**11**:1487–1491.
- Oktay K, Economos K, Kan M, Rucinski J, Veeck L, Rosenwaks Z. Endocrine function and oocyte retrieval after autologous transplantation of ovarian cortical strips to the forearm. *JAMA* 2001;**286**:1490–1493.
- Oktay K, Buyuk E, Veeck L, Zaninovic N, Xu K, Takeuchi T et al. Embryo development after heterotopic transplantation of cryopreserved ovarian tissue. *Lancet* 2004;**363**:837–840.
- Piver P, Aniot C, Agnani G, Pech JC, Rohrllich PS, Vidal F et al. Two pregnancies obtained after a new technique of autotransplantation of cryopreserved ovarian tissue. *Hum Reprod* 2009;**24**:10–35.
- Riboli E, Hunt KJ, Slimani N, Ferrari P, Norat T, Fahey M et al. European Prospective Investigation into Cancer and Nutrition (EPIC): study of populations and data collection. *Public Health Nutrition* 2002;**5**:1113–1124.
- Ries LAG. Cancer incidence and survival among children and adolescents: United States SEER program 1976–1995, 1999.
- Rosendahl M, Loft A, Byskov AG, Ziebe S, Schmidt KT, Andersen AN, Ottosen C, Andersen CY. Biochemical pregnancy after fertilization of an oocyte aspirated from a heterotopic autotransplant of cryopreserved ovarian tissue: case report. *Hum Reprod* 2006;**21**:2006–2009.
- Sanchez-Serrano M, Crespo J, Mirabet V, Cobo AC, Escriba MJ, Simon C, Pellicer A. Twins born after transplantation of ovarian cortical tissue and oocyte vitrification. *Fertil Steril* 2010;**93**:268.e11–3.
- Silber SJ. Transplantation of a human testis for anorchia. *Fertil Steril* 1978;**30**:181–187.
- Silber SJ. The Y chromosome in the era of intracytoplasmic sperm injection: a personal review. *Fertil Steril* 2011;**95**:2439–2448.
- Silber SJ, Gosden RG. Ovarian transplantation in a series of monozygotic twins discordant for ovarian failure. *N Engl J Med* 2007;**356**:1382–1384.
- Silber SJ, Lenahan KM, Levine DJ, Pineda JA, Gorman KS, Friez MJ et al. Ovarian transplantation between monozygotic twins discordant for premature ovarian failure. *N Engl J Med* 2005;**353**:58–63.
- Silber SJ, DeRosa M, Pineda J, Lenahan K, Grenia D, Gorman K, Gosden RG. A series of monozygotic twins discordant for ovarian failure: ovary transplantation (cortical versus microvascular) and cryopreservation. *Hum Reprod* 2008a;**23**:1531–1537.
- Silber SJ, Grudzinskas G, Gosden RG. Successful pregnancy after microsurgical transplantation of an intact ovary. *N Engl J Med* 2008b;**359**:2617–2618.
- Silber SJ, Kagawa N, Kuwayama M, Gosden R. Duration of fertility after fresh and frozen ovary transplantation. *Fertil Steril* 2010;**94**:2191–2196.
- Snieder H, MacGregor AJ, Spector TD. Genes control the cessation of a woman's reproductive life: a twin study of hysterectomy and age at menopause. *J Clin Endocrinol Metab* 1998;**83**:1875–1880.
- Su LL. Monoamniotic twins: diagnosis and management. *Acta Obstet Gynecol Scand* 2002;**81**:995–1000.
- Van Asselt KM, Kok HS, Pearson PL, Dubas JS, Peeters PH, Te Velde ER, Van Noord PAH. Heritability of menopausal age in mothers and daughters. *Fertil Steril* 2004;**82**:1348–1351.